


## A rare case of enamel pearl in canine tooth

Ana Carolina Ramos Mariz <sup>1\*</sup>  
Gabriela Meyge de Brito <sup>2</sup>  
Daniela Adorno Farias <sup>3</sup>  
André Wilson Machado <sup>2</sup>  
Paulo Sérgio Flores Campos <sup>1</sup>

### Abstract:

The enamel pearl (EP) is a dental developmental anomaly that usually manifests in furcation areas, and is uncommon in uniradicular teeth. We present a case of EP on the vestibular surface of tooth 13 in a 38-year-old patient, who was submitted to multislice computed tomography (MSCT) for orthognathic surgery planning. The attenuation coefficient (3.070 HU) allowed the condition to be classified as a true EP.

**Keywords:** Tooth Abnormalities; Multidetector Computed Tomography; Tooth, Impacted

<sup>1</sup> Federal University of Bahia, Dentistry and Health section, Department of Oral Radiology - Salvador - Bahia - Brasil.

<sup>2</sup> Federal University of Bahia, Dentistry and Health section, Department of Orthodontics - Salvador - Bahia - Brasil.

<sup>3</sup> University of Chile, Faculty of Dentistry, Department of Oral Pathology - Santiago - Santiago - Chile.

#### Correspondence to:

Ana Carolina Ramos Mariz.  
E-mail: anacrmriz@gmail.com

Article received on July 12, 2018.  
Article accepted on July 18, 2018.

DOI: 10.5935/2525-5711.20180007



## INTRODUCTION

Enamel pearls (EPs) are ectopic deposits of enamel that normally manifest in the furcation region and close to the cemento–enamel junction<sup>1,2</sup>, and show a prevalence ranging between 0.82% and 5.1%<sup>1,3-5</sup>. They mainly affect the permanent maxillary molars<sup>4,6,7</sup>, especially the second and third molars<sup>1,2,8</sup> and vary from 0.3 to 4 mm in diameter<sup>1,3,6</sup>. Microscopically, EPs present prismatic enamel and can be classified as true pearls (consisting of enamel only), enamel–dentin pearls (made up of enamel and tubular dentin) and enamel–dentin–pulp pearls<sup>1,3,5-7</sup>.

The etiopathogenesis of EPs is unknown, but the most widely accepted theory is that these pearls result from a localized developmental activity of the remnant of Hertwig's epithelial root sheath<sup>1-4,6,8-10</sup>. Ameloblasts are believed to differentiate into functioning cells that produce enamel deposits on tooth roots<sup>1-3,5,8-10</sup>. The possibility of the condition being of a hereditary nature has been admitted<sup>7,10,11</sup>.

The aim of this report was to relate a rare case of EP in a permanent canine tooth evaluated by computed tomography.

## CASE REPORT

The patient, a 38-year-old woman was submitted to multislice computed tomography (MSCT) for the purpose of planning orthognathic surgery, which revealed an compound odontoma beneath tooth 83, tooth 43 impacted and localized below the molars, and an EP in the vestibular cervical region of tooth 13 (Figure 1).

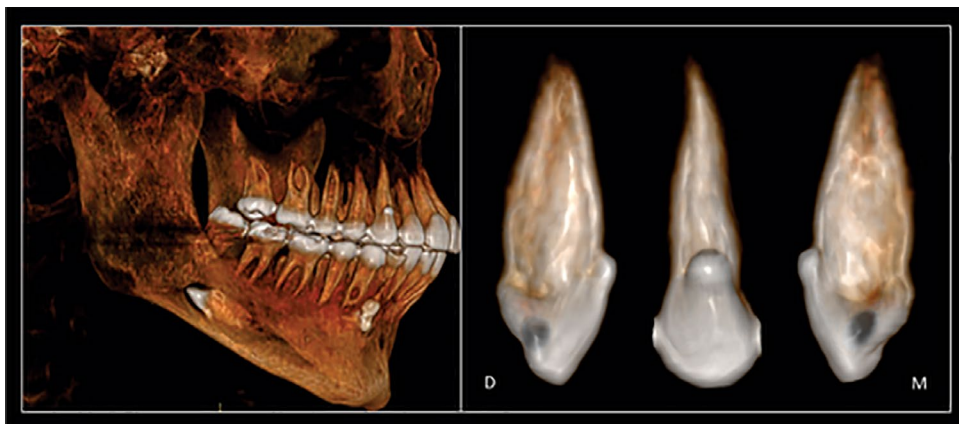
The attenuation coefficient of the EP (3.070 HU) was shown to be equivalent to that of the enamel of tooth 18 (3.073 HU) (Figure 2), which led us to the diagnosis of a true EP.

## DISCUSSION

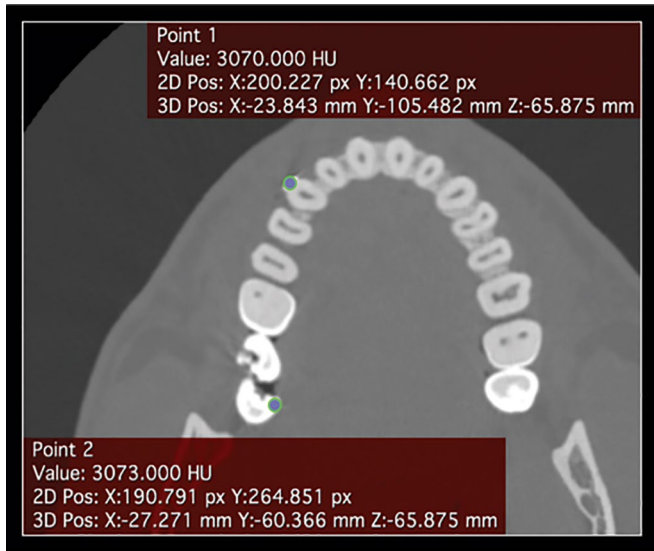
The occurrence of EPs in uniradicular teeth is uncommon<sup>10,12</sup>, because prevalence studies have not reported cases of EP in uniradicular teeth<sup>1,5</sup>. To the best of our knowledge, only two cases of EP in uniradicular teeth have been reported: one in a mandibular central incisor<sup>12</sup> and the other in a mandibular first premolar<sup>10</sup>. Among the 45.785 teeth in a human tooth bank, the following data were observed: 287 molars (0.627%) with one EP; 57 molars (0.125%) with EPs; and 1 molar (0.002%) with 3 EPs; 26 premolars (0.057%) with one EP and 4 canines (0.009%) with one EP<sup>4</sup>.

The ectopic enamel of both pearls and cervical enamel projections has frequently been associated with periodontal destruction in molars<sup>6,7,9,12,13</sup>. In these cases, attachment of the periodontal ligament does not occur appropriately, which makes it difficult to control biofilm and restricts access for root scaling and planing<sup>12</sup>, thus contributing to the formation of periodontal pockets<sup>6-8,10,12</sup>. Patients who present EP need follow-up and prevention programs for preventing the appearance of periodontal disease<sup>2,6</sup>. Some authors have suggested that EPs must be removed to allow appropriate biofilm control and prevent future (clinical) attachment loss<sup>6,10</sup>.

Radiographically, EPs are seen as dense, circumscribed radiopacities in the crown or root of the affected tooth<sup>5,6</sup>. The density, architecture and localization of the EP may be better defined by the high resolution of cone beam computed tomography (CBCT)<sup>1,9</sup>. This exam modality also helps to evaluate the distance between the EP and alveolar bone crest or furcation area, which provides a more precise prognosis of the future risk of periodontal bone loss<sup>12</sup>. The MSCT used in the present case showed only enamel in the constitution of the pearl, allowing us to classify it as a true pearl.



**Figure 1.** 3D reconstruction showing tooth 43 in an ectopic position, compound odontoma beneath tooth 83, and PE on buccal aspect of tooth 13 (on detail).



**Figure 2.** Axial image, bone window, showing the measurement of HU on EP (point 1) and on enamel of tooth 18 (point 2).

## REFERENCES

1. Akgül N, Caglayan F, Durna N, Sümbüllü MA, Akgül HM, Durna D. Evaluation of enamel pearls by cone-beam computed tomography (CBCT). *Med Oral Patol Oral Cir Bucal*. 2012;17:e218-22.
2. Shojaeian S, Ghoddsi J, Hajian S. A case report of maxillary second molar with two palatal root canals and a furcal enamel pearl. *Iran Endod J*. 2013;8:37-9.
3. Darwazeh A, Hamasha AA. Radiographic evidence of enamel pearls in Jordanian dental patients. *Oral Surg Oral Med Oral Pathol Oral Radiol Endod*. 2000;89:255-8.
4. Chrcanovic BR, Abreu MH, Custódio AL. Prevalence of enamel pearls in teeth from a human teeth bank. *J Oral Sci*. 2010;52:257-60.
5. Çolak H, Hamidi MM, Uzgur R, Ercan E, Turkal M. Radiographic evaluation of the prevalence of enamel pearls in a sample adult dental population. *Eur Rev Med Pharmacol Sci*. 2014;18:440-4.
6. Romeo U, Palaia G, Botti R, Nardi A, Del Vecchio A, Tenore G, et al. Enamel pearls as a predisposing factor to localized periodontitis. *Quintessence Int*. 2011;42:69-71.
7. Pardiñas-López S, Warren RN, Bromage TG, Matei IC, Khouly I. Treatment of an Unusual Non-Tooth-Related Enamel Pearl (EP) and 3 Teeth-Related EPs with Localized Periodontal Disease Without Teeth Extractions: A Case Report. *Compend Contin Educ Dent*. 2015;36:592-9.
8. Kaminagakura E, Salmom CR, Fonseca DC, Lopes MCA, Tango RN. Prevalence and microscopic features of enamel pearls from permanent human molars. *Braz J Oral Sci*. 2011;10:268-71.
9. Versiani MA, Cristescu RC, Saquy PC, Pécora JD, de Souza-Neto MD. Enamel pearls in permanent dentition: case report and micro-CT evaluation. *Dentomaxillofac Radiol*. 2013;42:20120332.
10. Zenóbio EG, Vieira TR, Bustamante RPC, Gomes HE, Shibli JA, Soares RV. Enamel Pearls Implications on Periodontal Disease. *Case Rep Dent*. 2015;2015:236462.
11. Saini T, Ogunleye A, Levering N, Norton NS, Edwards P. Multiple enamel pearls in two siblings detected by volumetric computed tomography. *Dentomaxillofac Radiol*. 2008;37:240-4.
12. Sharma S, Malhotra S, Baliga V, Hans M. Enamel pearl on an unusual location associated with localized periodontal disease: A clinical report. *J Indian Soc Periodontol*. 2013;17:796-800.
13. Risnes S, Segura JJ, Casado A, Jiménez-Rubio A. Enamel pearls and cervical enamel projections on 2 maxillary molars with localized periodontal disease: case report and histologic study. *Oral Surg Oral Med Oral Pathol Oral Radiol Endod*. 2000;89:493-7.