


Varied radiographic appearances of complex odontoma - Case series and clinical-radiographic review

Vidisha Gargi ^{1*}
Ravi Prakash SM ¹
Nagaraju K ¹
Swati Gupta ¹

Abstract:

Odontome is most common benign odontogenic tumour. Radiographically and histologically it is characterized by production of mature enamel, dentin, cementum and pulp tissue. The structural relationship vary from nondescript mass of dental tissue referred to as complex odontome and multiple well-formed teeth (denticles) known as compound odontome. Odontomes are often found during routine radiographic investigations and are the most common cause of delayed eruption of the permanent teeth and sometimes it may itself erupt in the oral cavity. We are presenting a case series of complex odontomes with varied clinical features and radiographic appearances which may be helpful for the clinician to achieve accurate diagnosis in order to avoid subsequent complications.

Keywords: Ameloblastoma, Odontoma, Hamartoma.

¹ Subharti dental college, Department of Oral Medicine and Radiology - Meerut - Uttar pradesh - India.

Correspondence to:

Vidisha Gargi.
E-mail: vidishagargi@gmail.com

Article received on January 17, 2018.
Article accepted on February 20, 2018.

DOI: 10.5935/2525-5711.20180033



INTRODUCTION

Odontoma is a benign odontogenic tumor. The term odontoma was first coined by Broca (1866); he defined it as a tumor formed by an overgrowth of complete dental tissues¹. They are the product of growth of differentiated mesenchymal and epithelial cells, where ameloblasts and odontoblasts form enamel and dentin and are anomalously or defectively deposited^{2,3}. The odontomas is perhaps more accurately defined as a hamartoma than a true neoplasm⁴. Histologically two forms of odontomas are recognized, complex and compound odontoma.

Cahn and Blum⁵ hypothesized that ameloblastic fibroma differentiates into odontoma whereas Eversole et al.⁶ postulated that the individual mixed odontogenic tumors are incapable of further differentiation. According to the World Health Organization (WHO) classification of benign odontogenic tumors, a complex odontoma is a malformation in which all the dental tissues are represented, individual tissues being mainly well formed but occurring in a more or less disorderly pattern; whereas a compound odontoma is a malformation in which all the dental tissues are represented in a more orderly pattern than in the complex odontoma so that the lesion consists of many tooth like structures⁷.

Complex odontome is rare as compared to compound odontomes. Odontoma etiology is unknown but several factors are implicated such as trauma, infections, genetic mutations, odontoblastic hyperactivity or alterations of the dental development control gene. Most of these tumors are discovered during the patient's second to third decade of life, and do not exhibit clear gender predilection^{8,9}. The complex odontoma are slow growing, expanding lesions that are usually detected in the second decade of life^{10,11}.

The lesions are invariably asymptomatic and are usually discovered on routine radiographic examinations. Most of the odontomas are associated with pathologic changes such as malformation, impaction, delayed eruption, mal-positioning, cyst formation or displacement and resorption of adjacent teeth, but only rarely are they seen to be associated with the absence of one or more contiguous teeth^{10,12}.

We present a series of seven cases of complex odontome illustrating varied clinical-radiographic features of odontomes (Table 1).

DISCUSSION

Odontomas constitute about 22% of all odontogenic tumors of the jaws¹³. WHO classification defines this lesion as "a malformation, in which all the dental tissues are represented, individual tissues being mainly well formed but occurring in more or less disorderly pattern"¹⁴. During the first decades of last century, the term odontoma meant not only odontogenic tumors, but rather included odontogenic and non odontogenic cysts as well as varied ossifying fibroid lesions of the jaws.

The second edition of the WHO histologic typing of odontogenic tumours classifies odontomas under the broad category of tumours containing odontogenic epithelium with odontogenic ectomesenchyme, with or without dental hard tissue formation. Under this classification three types of odontomas are listed: odontoameloblastoma, complex and compound odontoma¹⁴. Another classification given by H.M. Worth for odontomes was of ectodermal origin (Enameloma), of mesodermal origin (dentinoma, cementoma), of mixed ectodermal and mesodermal origin (complex composite odontome, compound composite odontome, geminated odontome, dilated odontome, including dens in dente)¹⁵.

According to 2005 WHO classification of odontogenic tumours, there are two types of odontomas, compound and complex type classified under benign tumors composed of odontogenic epithelium and odontogenic mesenchyme along with odontoameloblastoma and ameloblastic fibro-odontome which is considered as an immature precursor of complex odontoma¹⁴.

In the 4th edition of the World Health Organization Classification of Head and Neck tumours, odontomas are still classified under mixed epithelial and mesenchymal odontogenic tumours of benign type. In the current classification ameloblastic fibro-odontoma and odontoameloblastoma has been removed¹⁶. Odontoameloblastoma was removed as it only represents conventional ameloblastoma that happens to arise in association with an odontoma.

Odontomas have also been classified as central odontoma (which presents inside the bone), peripheral odontoma (which occur in the soft tissue covering the tooth bearing portion of jaws) and erupted odontoma

Table 1. Series of seven cases of complex odontoma illustrating varied clinical-radiographic features of odontoma

S. No	Age/Sex	Region	Clinical findings	Radiological appearance (As seen on OPG, occlusal, CBCT/CT scans)	Histopathology
1.	18yr/Male	Lower anterior	Missing 41,42,43, distally displaced 31, 32 Buccal and lingual cortical plate expansion (Fig. 1a)	well-defined bony mass with central bony lesion with spikes at the margin and surrounded by hypodensity (Fig. 1b,c)	Odontoameloblastoma
2.	22 yr/Female	Right maxilla	Missing 12,14 and15. Buccal and lingual cortical plate expansion (Fig. 2a)	Large expansile mixed lesion causing buccal and lingual cortical plate expansion surrounded by soft tissue capsule. (Fig. 2b,c)	Odontoameloblastoma
3.	20 yr/Female	Right mandible	Missing 45,46,47 Buccal and lingual cortical plate expansion (Fig. 3a)	Large mixed lesion, composed of an irregular shaped dense radiopaque mass, surrounded by a halo of radiolucency with definite boundary. 45, 46 was embedded in the radiopaque mass and 47 was displaced towards the coronoid process. (Fig. 3a,b)	Complex odontome
4.	12/male	Left mandible	Unerrupted 44 Expansion of buccal cortical plate (Fig. 4a)	Mixed lesion having internal structure of homogenous flocculent mass with a radiodensity of teeth. (Fig. 4b,c)	Complex odontome
5.	19/ Male	Left mandible	Extraoral sinus tract Tooth like structure seen Irt 37,38 region (Fig. 5a)	Homogeneous radiopaque mass distal to the mandibular first molar, disto-inferiorly displaced crown of the mandibular left second molar and inferior alveolar canal is pushed inferiorly. (Fig. 5b)	Complex odontome
6.	23/ Male	Left mandible	Intraoral sinus opening present Missing 38 (Fig. 6a)	Solitary radiopaque mass approx. 2×2 cm present on the superior aspect of impacted 38. A radiolucent rim encircling the mass is clearly evident and inferior alveolar nerve canal is pushed inferiorly. (Fig. 6b,c)	Complex odontome
7.	12/Female	Left mandible	Buccal and lingual cortical plate expanded Tooth like structure seen irt 36,37, 38 region (Fig. 7a)	Solitary, conglomerate mass approx. 3×2 cm present on the superior aspect of impacted 36 with missing 37 and 38. (Fig. 7b,c)	Complex odontome

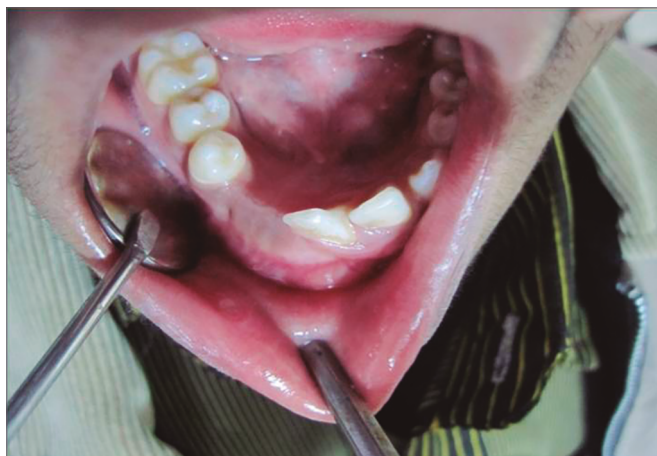

Figure 1. Missing 41,42,43, distally displaced 31, 32 Buccal and lingual cortical plate expansion.

according to their clinical presentation¹⁶. In this case series, all of the cases were centrally located but three cases showed tendency to erupt. The procedure of eruption of erupted odontomas in the oral cavity is

different as compared to the eruption pattern of normal teeth due to absence of periodontal ligament fibres.

Certain authors are of the view that since the complex odontome is associated with unerupted tooth, hence it is the eruptive force of the concerned uneruptive tooth that can lead to eruption of the odontoma in the oral cavity¹⁶. This theory of odontoma eruption may suit to this presented case too as in cases no. 5, 6 and 7, the odontoma was present coronal to the lesion. Certain authors like Ragalli¹⁷ were of the view that it is the growth of capsule that contributes to the eruption of odontoma.

Thomas and Goldman classification of Odontomes: Geminated composite odontomes (two or more, more or less developed teeth fused together), compound composite odontomes (made up of more or less rudimentary teeth), complex composite odontomes (calcified structure, which bear no great resemblance to the normal anatomical arrangement of dental tissue), dilated odontomes (crown or root part of tooth shows

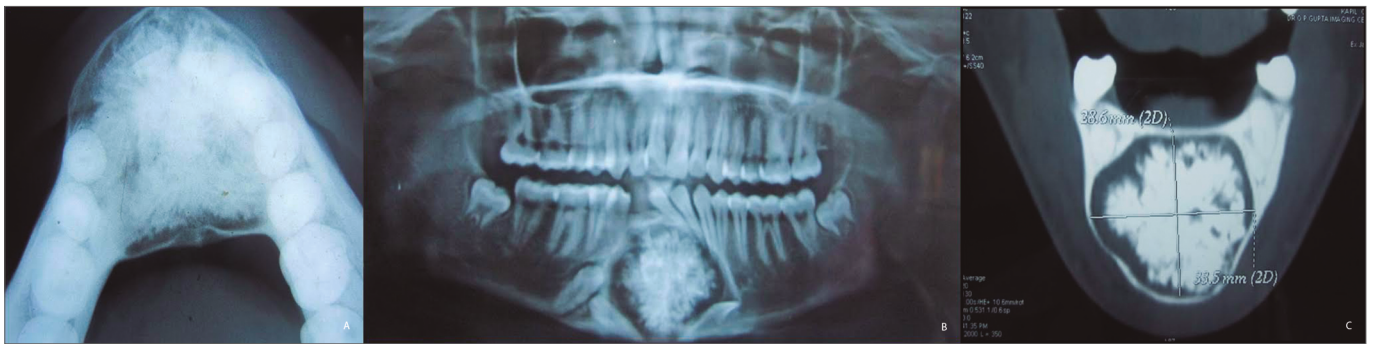

Figure 2. A. Missing 41,42,43, distally displaced 31, 32 Buccal and lingual cortical plate expansion. B, C. Large expansile mixed lesion causing buccal and lingual cortical plate expansion surrounded by soft tissue capsule.

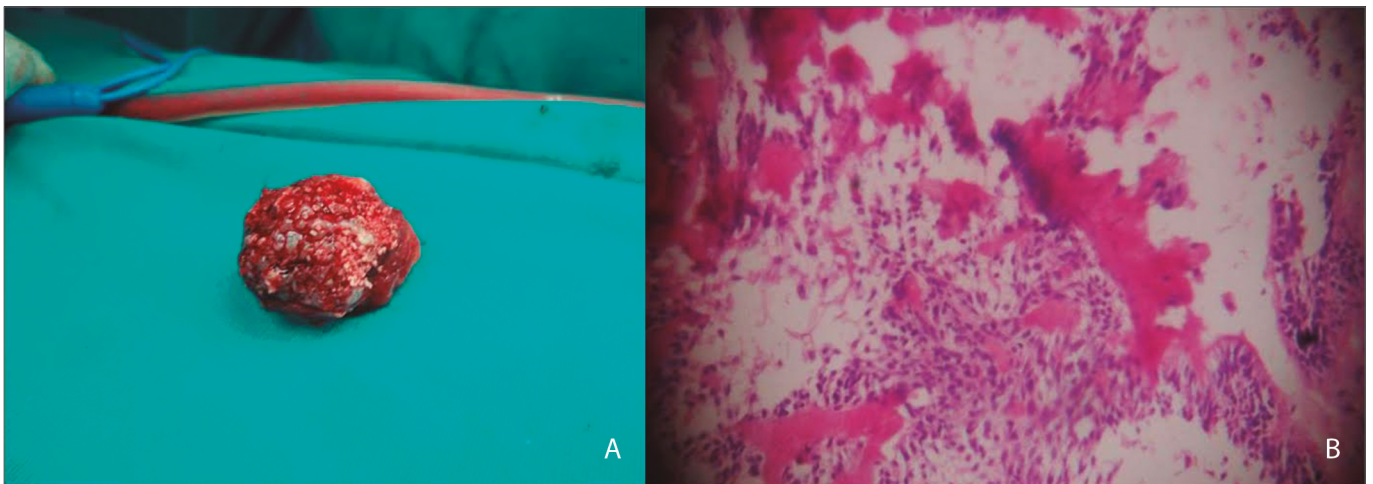


Figure 3. A. Missing 45,46,47 Buccal and lingual cortical plate expansion. B. Large mixed lesion, composed of an irregular shaped dense radiopaque mass, surrounded by a halo of radiolucency with definite boundary. 45, 46 was embedded in the radiopaque mass and 47 was displaced towards the coronoid process.

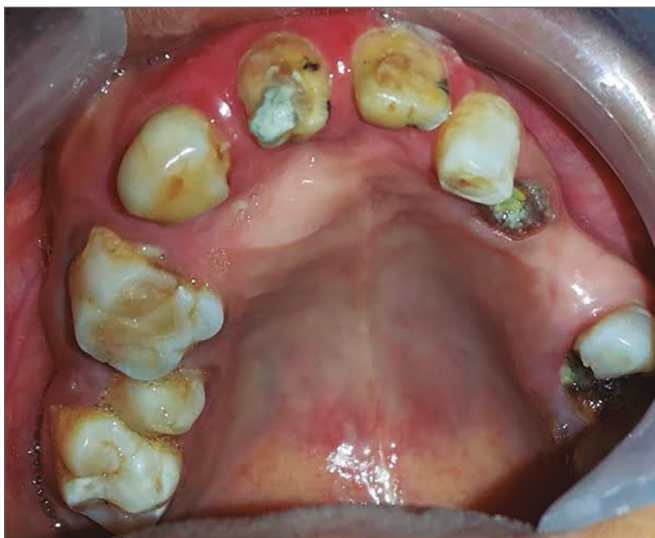

Figure 4. Unerupted 44 Expansion of buccal cortical plate. Mixed lesion having internal structure of homogenous flocculent mass with a radiopacity of teeth.

marked enlargement), cystic odontomas (normally encapsulated by fibrous connective tissues in a cystic wall of cyst).

The complex odontomas are usually located in the posterior mandible, while composite odontomas are more often found in the anterior maxilla¹⁸. In the present case series all the lesions were located in posterior maxilla except two cases where one case was located in anterior mandible and another one in anterior maxilla. Odontomas are incidental findings on routine radiographs. Retention of deciduous teeth, unerupted permanent teeth, cortical expansion and teeth displacement are all indicators for a possible odontomas¹⁹. They are symptomatic with expansion, local and/or radiating pain and neurosensory deficit when secondarily infected²⁰. In all case reports in the series cortical expansion was a common finding along with teeth displacement.

The radiographic findings of odontomas depend on their stage of development and degree of mineralization. The first stage is characterized by radiolucency due to lack of calcification. Partial calcification is observed in the intermediate stage, while in the third stage the lesion usually appears as radiopaque masses surrounded by radiolucent areas corresponding to the connective tissue histologically^{18,19}. The radiopaque mass invariably

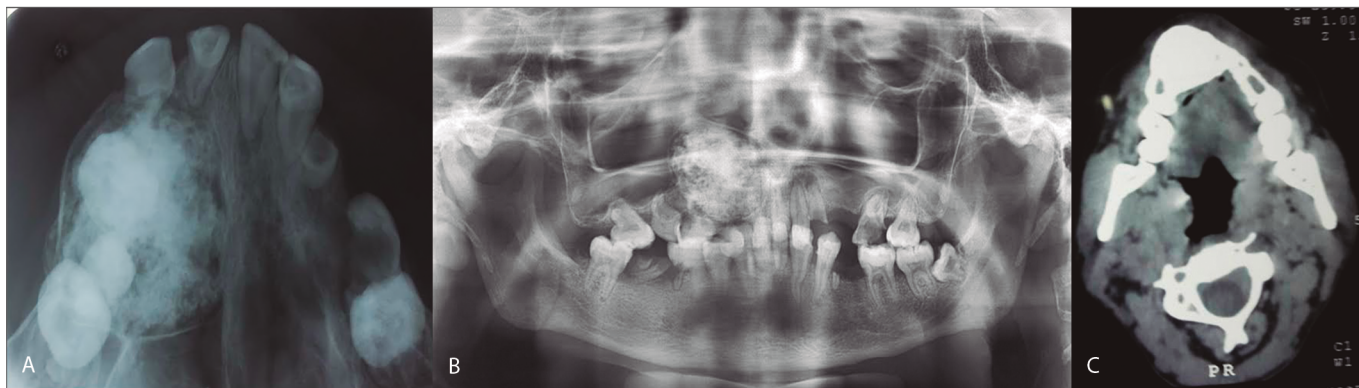

Figure 5. A. Extraoral sinus tract Tooth like structure seen Irt 37,38 region. B. Homogeneous radiopaque mass distal to the mandibular first molar, disto-inferiorly displaced crown of the mandibular left second molar and inferior alveolar canal is pushed inferiorly.

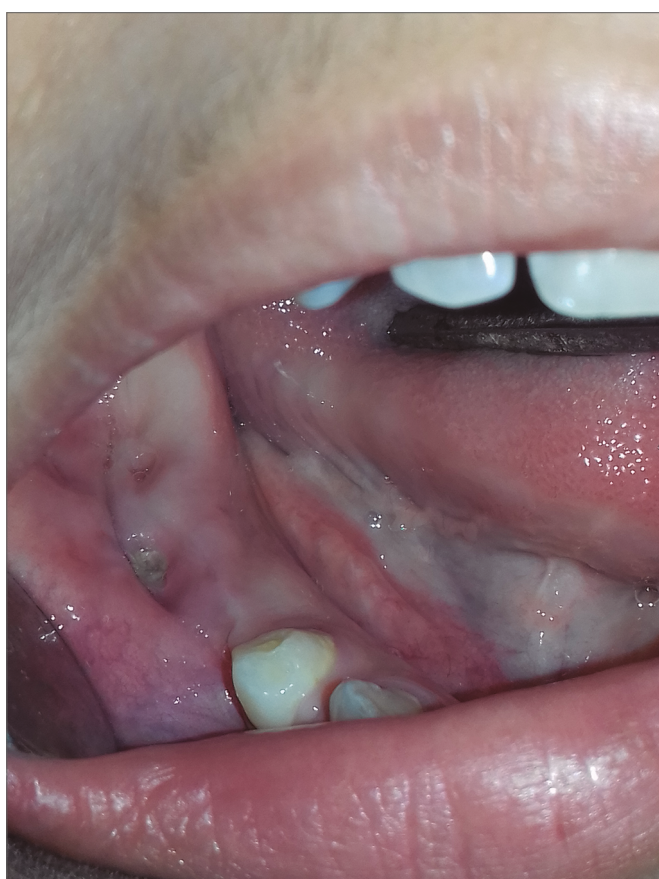

Figure 6. Intraoral sinus opening present Missing 38. Solitary radiopaque mass approx. 2x2 cm present on the superior aspect of impacted 38. A radiolucent rim encircling the mass is clearly evident and an inferior alveolar nerve canal is pushed inferiorly.

is round or ovoid and usually has smooth margins. The margins sometimes appear lobulated or spikelike. The internal elements occasionally have a mottled appearance and sometimes the calcified mass takes on a sunburst appearance²¹.

In this case series' most of the cases appear as predominantly radiopaque mass while cases no. 1 and 2 have mixed appearances and all the lesions are surrounded by a thin radiolucent zone consisting of a connective tissue capsule which corresponds to follicle of normal tooth. Further this zone is surrounded by a thin sclerotic line corresponding to the cortical outline of normal tooth crypt²².

In almost all the cases the radiopaque mass causes either displacement of teeth or impeded their eruption. In the first case, the lesion has characteristic sun-burst appearance but is surrounded by radiolucent rim and around it there is severe displacement of adjacent teeth. In the second case, the bony lesion has ground glass appearance surrounded by radiolucent rim. In third and fourth case the bony lesion has cotton-wool appearance with displacement of adjacent teeth. The other three cases appeared as prominent radiopaque mass impeding the eruption of permanent teeth. The present case series focuses on the varied radiographic appearances of odontomes.

When complex odontoma is in its intermediate phase it resembles other lesions such as fibroosseous lesions, calcifying cystic odontogenic tumors, fibrous dysplasia and chronic osteomyelitis²³. Likewise differential diagnosis must also include hypercementosis which is attached to a part of the root and is usually separated from the periapical bone by the radiolucent periodontal ligament space, which surrounds the entire root. Condensing osteitis may usually be ruled out because it usually occurs at the periapex of non-vital tooth and doesn't have a radiolucent rim. Periapical osteosclerosis is usually quite irregular in shape with the absence of radiolucent border²¹.

Histologically, odontomas comprise varying amount of enamel, pulp tissue, enamel organ and

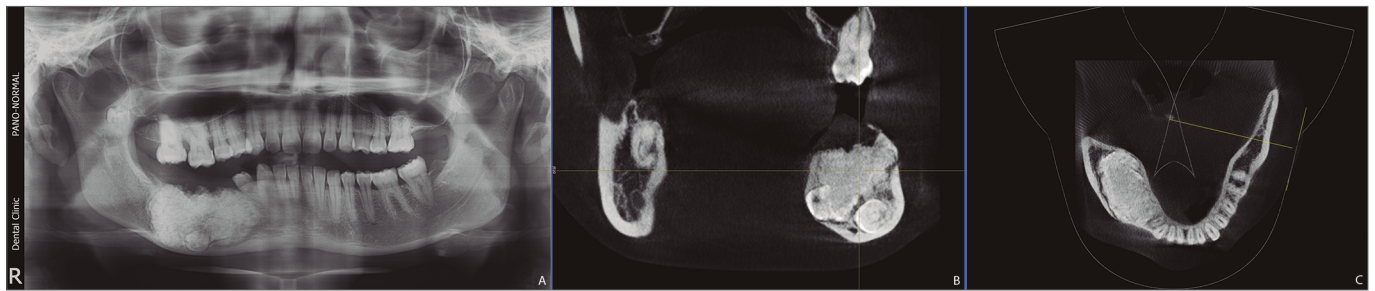


Figure 7. A. Buccal and lingual cortical plate expanded Tooth like structure seen irt 36,37, 38 region. B, C. Solitary, conglomerate mass approx. 3×2 cm present on the superior aspect of impacted 36 with missing 37 and 38.

cementum. The connective tissue capsule is similar to that of dental follicle. Ghost cells are often seen along with spherical dystrophic calcification, enamel concretions and sheets of dysplastic dentin¹⁹. Case 1 and 2 were initially diagnosed as odontoameloblastoma but due to deletion of this entity from the recent WHO classification published in 2017 and with histopathologists opinion we reclassified it as odontomes of complex type.

Since odontomas are well capsulated lesions and have less chances of recurrence, the management comprises of a conservative surgical excision. Nevertheless periodic examination is necessary to evaluate healing and recurrence if any.

CONCLUSION

Literature review revealed a wide panorama of descriptive aspects of odontoma and here we present a case series of complex odontome with varied clinical features and radiographic appearance. Odontoma, being the most common odontogenic tumors; are detected through routine radiographic examination. It is therefore advisable to timely and accurate diagnosis in order to avoid subsequent complications and it is further recommended to perform histopathological analysis so as to discard the possibility of association of some other type of odontogenic tumors.

REFERENCES

1. Broca P. *Traite Des Tumeurs*. V. Paris: P. Asselin; 1866.
2. Padmanabhan MY, Pandey RK, Aparna R. Erupted composite odontoma associated with malformed teeth - unusual dental aberrations following maxillofacial trauma. *Rom J Morphol Embryol*. 2013;54:1153-6.
3. Sreedharan S, Krishnan IS. Compound odontoma associated with impacted maxillary incisors. *J Indian Soc Pedod Prev Dent*. 2012;30:275-8.
4. Shekar S, Rao SR, Gunasheela B, Supriya N. Erupted compound odontome. *J Oral Maxillofac Pathol*. 2009;13:47-50.
5. Hawkins PL, Sadeghi EM. Ameloblastic fibro-odontoma: report of case. *J Oral Maxillofac Surg*. 1986;44:1014-9.
6. Slootweg PJ. An analysis of the interrelationship of the mixed odontogenic tumors-ameloblastic fibroma, ameloblastic fibro-odontoma, and the odontomas. *Oral Surg Oral Med Oral Pathol*. 1981;51:266-76.
7. Takeda Y, Tomich CE. Ameloblastic fibroodontoma. In: *World Health Organization Classification of Tumors (WHO)*. International Agency for Research on Cancer. Lyon: IARC Press; 2005.
8. Yadav M, Godge P, Meghana SM, Kulkarni SR. Compound odontoma. *Contemp Clin Dent*. 2012;3(Suppl 1):S13-5.
9. Bagewadi SB, Kukreja R, Suma GN, Yadav B, Sharma H. Unusually large erupted complex odontoma: A rare case report. *Imaging Sci Dent*. 2015;45:49-54.
10. Budnick SD. Compound and complex odontomas. *Oral Surg Oral Med Oral Pathol*. 1976;42:501-6.
11. Reichart AP, Philipsen HP. *Odontogenic tumors and allied lesions*. London: Quintessence; 2004.
12. Lee CH, Park GJ. Complex and compound odontomas are clinico-pathological entities. *Basic Appl Pathol*. 2008;1:30-3.
13. Amado Cuesta S, Gargallo Albiol J, Berini Aytés L, Gay Escoda C. Review of 61 cases of odontoma. Presentation of an erupted complex odontoma. *Med Oral*. 2003;8:366-73.
14. Kramer IRH, Pindborg JJ, Shear M; World Health Organization International Histological Classification of Tumours. *Histological Typing of Odontogenic Tumours*. 2nd ed. Berlin: Springer; 1992. p. 16-21.
15. Worth HM. *Principles and Practice of Oral Radiographic Interpretation*. Chicago: Year Book Medical Publishers; 1963. p. 420-38.
16. Speight PM, Takata T. New tumour entities in the 4th edition of the World Health Organization Classification of Head and Neck tumours: odontogenic and maxillofacial bone tumours. *Virchows Arch*. 2017. DOI: 10.1007/s00428-017-2182-3. [Epub ahead of print]
17. Junquera L, de Vicente JC, Roig P, Olay S, Rodríguez-Recio O. Intraosseus odontoma erupted into the oral cavity: an unusual pathology. *Med Oral Patol Oral Cir Bucal*. 2005;10:248-51.
18. Ragallli F. Odontogenic tumors. In: Barwes L, ed. *Surgical Pathology of the Head and Neck*. 3rd ed. New York: Informa Healthcare; 2007. p. 1202-37.
19. Cohen DM, Bhattacharyya I. Ameloblastic fibroma, ameloblastic fibro-odontoma, and odontoma. *Oral Maxillofacial Surg Clin North Am* 2004;6:375-84.
20. Reichart PA, Philipsen HP. Complex odontoma. In: Reichart PA, Philipsen HP. *Odontogenic tumors and allied lesions*. New Delhi: Quintessence Publishing; 2005. p. 141-7.

-
21. Langias RP, Langland OE, Nortjé CJ. Diagnostic imaging of the Jaws. 1st ed. Baltimore: Williams and Wilkins; 1995. p. 319-21.
22. Thoma KM, Goldman HM. Oral Pathology. 5th ed. St Louis: CV Mosby; 1960. p. 1221-2.
23. Philipsen HP, Reichart PA, Praetorius F. Mixed odontogenic tumors and odontomas. Considerations on interrelationship. Review of the literature and presentation of 134 new cases of odontomas. Oral Oncol. 1997;33:86-99.