

Rare mucinous cystadenoma of minor salivary glands: Clinicopathologic analysis of 2 cases and review of literature

Denise Hélen Imaculada
Pereira de Oliveira ¹

Valéria Souza Freitas ³

Domingos Flávio Saldanha
Pacheco ²

Pedro Paulo de Andrade
Santos ²

Lélia Maria Guedes Queiroz ²

Lélia Batista de Souza ²

Abstract:

Cystadenoma is a rare benign tumor of the salivary glands exhibiting clinical findings very similar to mucocele and, microscopically it may be confused with other lesions such as salivary duct cyst and cheilitis glandularis. It may be classified into two variants: papillary and mucinous, papillary variety being more common than mucinous with very few cases reported in literature. The aim of this work was reporting two cases of oral mucinous cystadenoma, and reviewing the literature regarding clinicopathologic aspects, differential diagnosis and therapeutic management specific to these tumors.

Keywords: Salivary Gland Neoplasms; Minor Salivary Glands; Adenolymphoma

¹ Universidade Federal do Ceará.

² Universidade Federal do Rio Grande do Norte.

³ Universidade Estadual de Feira de Santana, Odontologia.

Correspondence to:

Denise Hélen Imaculada Pereira de Oliveira.
E-mail: denisehelen2011@hotmail.com

Article received on August 18, 2017.
Article accepted on August 22, 2017.

DOI: 10.5935/2525-5711.20170021



INTRODUCTION

A choristoma is defined as a tumour-like mass of normal cells or tissue that develops in an abnormal location¹. These lesions may be composed of different types of tissues whose only similarity is their close association in fetal development, and are designated according to the tissues from which they derive (e.g. salivary gland, cartilage, bone, glia, gastric mucosa)^{2,3}. Osseous choristoma is an uncommon alteration of the soft tissues in the oral cavity. Clinically, these lesions were described as a hard mass, either pedunculated or sessile and the most frequent topographical region is the posterior third of the tongue^{1,4}. Other locations for this lesion to arise are extremely rare⁵. The treatment of choice is a surgical excision with uneventful healing. Recurrence or malignant transformation has not been reported^{2,6}. This report describes a rare case of the osseous choristoma in the maxillary alveolarmucosa.

CASE REPORT

A 37 years-old female was referred for diagnostic evaluation of a nodule involving the alveolar mucosa of the maxillary premolar region, present for about 6 months (Figure 1). The lesion was 15 mm in diameter and caused discomfort during chewing but was otherwise asymptomatic. Examination by palpation revealed a smooth, firm, well circumscribed, mobile, non-painful mass in the right maxillary alveolar mucosa. Radiologically, neither erosion of the underlying bone nor endodontic and periodontal lesions were present. Excisional biopsy of the lesion was performed under local anesthesia and during the procedure noticed the integrity of the adjacent periosteum, showing that the lesion did not have correlation with the alveolar bone. The surgical specimen was fixed in 10% neutral buffered formalin for 24 hours and, following common practice, embedded in paraffin. Sections, 4 µm thick, were stained with hematoxylin and eosin (H&E), for histological evaluation.

Microscopic examination after decalcification revealed a nodule of bone surrounded by connective tissue with epithelium. The osseous layer was of mature and dense lamellar bone. The connective tissue was thin and fibrous, well-circumscribed by stratified squamous epithelium of the gingival surface (Figure 2 and 3). The final diagnosis was gingival osseous choristoma. The patient was kept under regular follow-up and there is no evidence of disease in two years.

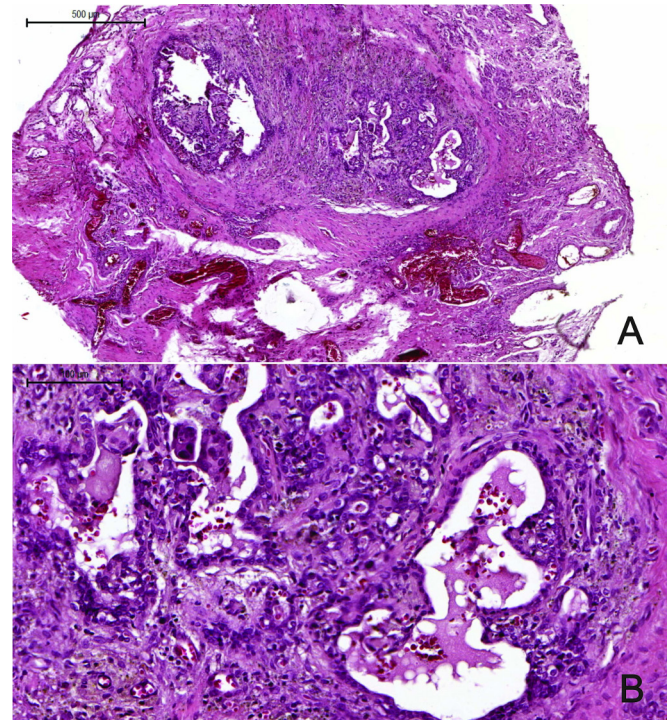


Figure 1. Mucinous cystadenoma. (A) Wide, well-delimited cystic space exhibiting intraluminal multicystic proliferations intermingled by hemorrhagic exudate; (B) Peripherally, these cystic spaces were limited by a double layer of cells cuboidal with focal mucous cells. In such spaces, there were variable amounts of mucinous material.

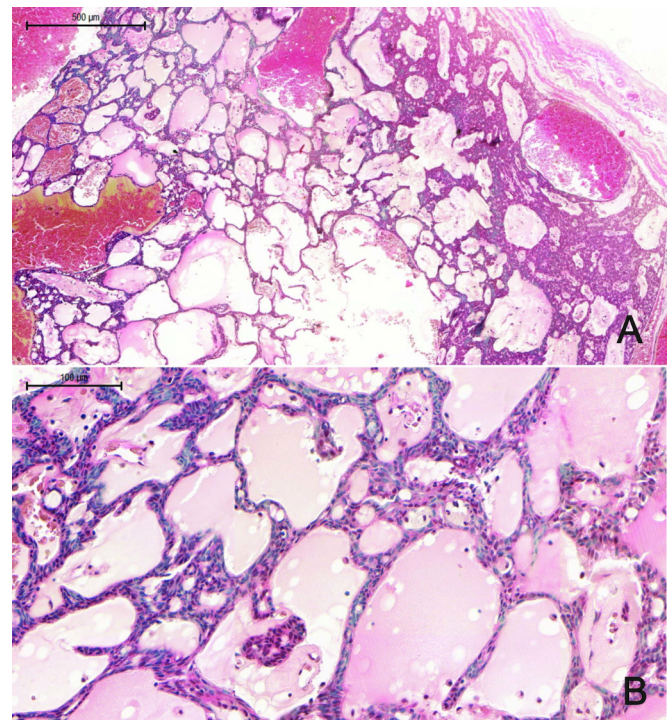


Figure 2. Mucinous cystadenoma. (A) Multicystic spaces without papillary projections; (B) Showed cystic spaces lined by cuboidal cells and hematoxyphilic material within the cystic space is suggestive of its origin (glycosaminoglycans or mucopolysaccharides)

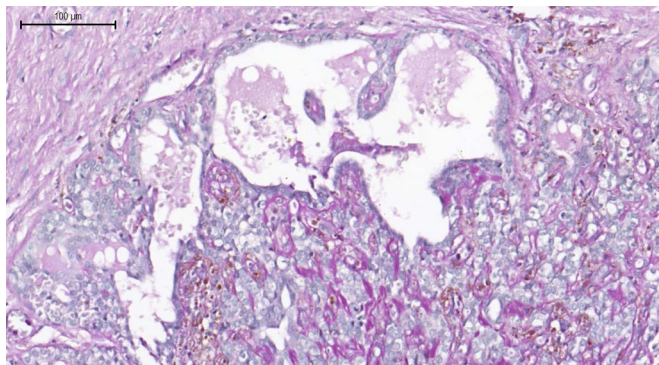


Figure 3. Mucinous cystadenoma. Periodic acid-Schiff (PAS) - positive materials inside of the multicystic spaces.

DISCUSSION

Oral choristomas were described for the first time in 1990 by Berry⁷, and the majority of lesions reported to date are located on the tongue^{5,8}, most frequently near the circumvallate papillae or foramen cecum. In the present case, however, the lesion is located in a alveolar mucosa, and only one case was in periodontium at lingual mandibular mucosa⁹. There are not aware of the publication of an osseous choristoma in similar location.

Although there are many theories of pathogenesis of osseous choristoma, it is still uncertain whether this lesion is developmental, neoplastic, or reparative^{5,10}. Many authors support embryonic rests as an origin of choristomas¹¹. It is also believed that pluripotent mesenchymal cells differentiate into osteocytes or chondrocytes. Metaplastic ossification can also result from trauma or chronic inflammation. In this case, soft tissue trauma was not reported by the patient¹¹.

The age range for reported cases of intraoral choristoma is between 8 and 73 years; however, the majority have been diagnosed in the women between the ages of 20 and 40 years^{4,6}. Clinically, the choristoma develops as a firm pedunculated nodular lesion between 0.5 and 2 cm in size. Most patients are unaware of the lesion, but symptoms of pain, dysphagia, gagging, choking and nausea have been reported, mainly when the lesion is in the tongue^{4,6}. In this presented case the lesion was asymptomatic.

Since the intraoral choristomas is rare, most such lesions are misdiagnosed as other soft tissue tumors⁵. The clinical differential diagnosis of osseous choristoma depends on the location. In the alveolar mucosa, it has to be distinguished from a fibroma, peripheral osteoma, or fibrous hyperplasia⁵.

The intraoral choristoma is treated by means of surgical excision, recurrence and malignant transformation has not been reported^{2,6}. The excised area was healed and free of recurrence to date.

CONCLUSION

In conclusion, this report has presented a rare location of a choristoma in a female patient, which by the clinical appearance and microscopic findings was shown to be an osseous choristoma presented in alveolar mucosa. To our knowledge, few cases of gingival osseous choristoma have been reported in the English language literature, and the clinical differential diagnoses are very important for the practitioners.

CONFLICT OF INTEREST

The authors declare that they have no conflict of interest.

ACKNOWLEDGMENTS

We are grateful to the Department of pathology for its substantial contribution in the cession of the histological images.

REFERENCES

1. Matsushita K, Tahara M, Sato H, Nakamura E, Fujiwara T. Cartilaginous choristoma deep in the upper midline oral vestibule. *Br J Oral Maxillofac Surg.* 2004;42:436-438. DOI: <http://dx.doi.org/10.1016/j.bjoms.2004.06.007>
2. Psomopoulou M, Antoniadou K. Submental osseous choristoma: a case report. *J Oral Maxillofac Surg.* 1998;56:666-7. DOI: [http://dx.doi.org/10.1016/S0278-2391\(98\)90470-0](http://dx.doi.org/10.1016/S0278-2391(98)90470-0)
3. Chou L, Hansen LS, Daniels TE. Choristoma of the oral cavity a review. *Oral Surg Oral Med Oral Pathol.* 1991;72:584-93. PMID: 1745517 DOI: [http://dx.doi.org/10.1016/0030-4220\(91\)90498-2](http://dx.doi.org/10.1016/0030-4220(91)90498-2)
4. Andressakis DD, Pavlakis AG, Chrysomali E, Rapidis AD. Infected lingual osseous choristoma. Report of a case and review of the literature. *Med Oral Patol Oral Cir Bucal.* 2008;13:E627-32.
5. Tohill MJ, Green JG, Cohen DM. Intraoral osseous and cartilaginous choristomas: Report of three cases and review of the literature. *Oral Surg Oral Med Oral Pathol.* 1987;63:506-10. PMID: 3472154 DOI: [http://dx.doi.org/10.1016/0030-4220\(87\)90268-4](http://dx.doi.org/10.1016/0030-4220(87)90268-4)
6. Ishikawa M, Mizukoshi T, Notani K, Iizuka T, Amemiya A, Fukuda H. Osseous choristoma of the tongue. Report of two cases. *Oral Surg Oral Med Oral Pathol.* 1993;76(5):561-3. PMID: 8247498 DOI: [http://dx.doi.org/10.1016/0030-4220\(93\)90062-9](http://dx.doi.org/10.1016/0030-4220(93)90062-9)
7. Berry J. Fibro-chondroma of tongue. *Trans Pathol Soc Lond* 1990; 41:81-2.
8. Sheridan SM. Osseous choristoma: a report or two cases. *Br J Oral Maxillofac Surg.* 1984; 22:99-102 PMID: 6585229 DOI: [http://dx.doi.org/10.1016/0266-4356\(84\)90021-4](http://dx.doi.org/10.1016/0266-4356(84)90021-4)
9. Goswamy M, Tabasum S, Kudva P, Gupta S. Osseous choristoma of the periodontium. *J Indian Soc Periodontol.* 2012; 16(1):120-122. DOI: <http://dx.doi.org/10.4103/0972-124X.94619>
10. Shear M, Speight PM. *Cysts of the Oral and Maxillofacial Regions*, Oxford: Blackwell Munksgaard; 2007.
11. Chou L, Hansen LS, Daniels TE. Choristoma of the oral cavity a review. *Oral Surg Oral Med Oral Pathol.* 1991;72:584-93. PMID: 1745517 DOI: [http://dx.doi.org/10.1016/0030-4220\(91\)90498-2](http://dx.doi.org/10.1016/0030-4220(91)90498-2)