

Eight-year follow-up of central giant cell lesion treated with corticosteroid: Case report

Tila Fortuna Costa ^{1,2}
Juliana Borges de Lima
Dantas ¹
Daniel Santana Silva ¹
Sílvia Regina de Almeida Reis ³
Antônio Márcio Teixeira
Marchionni ⁴
Alena Ribeiro Alves Peixoto
Medrado ⁵

Abstract:

Introduction: Central giant-cell granulomas (CGCL) are benign, but occasionally aggressive, lesions that traditionally have been treated surgically. Nonsurgical treatments, such as intralesional corticosteroid injections, systemic calcitonin and interferon have been reported. The advantages of this therapy include its less-invasive nature, the probable lower cost to the patient and the preservation of important structures. **Objectives:** This paper aims to report a case of a pediatric patient with CGCL of the jaw, which was successfully treated with intralesional corticosteroid injections as its only therapy and discuss if there is an ideal waiting period between nonoperative treatment and the need for surgical intervention. **Methods and Materials:** an eight-year-old boy with a central giant cell lesion on the right side of the mandible was treated with intralesional corticosteroids injections. **Results and Conclusion:** After an eight-year follow-up, the patient's bony architecture was near normal. The panoramic radiography showed areas of new bone formation and neither recurrence nor side effects of the medication have been also detected. Is there an ideal waiting period between nonoperative treatment and the need for surgical intervention? It is estimated that a monitoring period of 6-8 years is necessary to determine the success of such treatment.

Keywords: Granuloma, Giant Cell; Triamcinolone Acetonide; Drug Therapy; Pathology, Oral.

¹ Escola Bahiana de Medicina e Saúde Pública.

² Faculdade Regional da Bahia.

³ Universidade Livre de Berlim.

⁴ Universidade Federal da Bahia.

⁵ Humana UFBA/FIOCRUZ.

Correspondence to:

Alena Ribeiro Alves Peixoto Medrado.
E-mail: alenamedrado@hotmail.com

Article received on June 7, 2017.

Article accepted on July 14, 2017.

DOI: 10.5935/2525-5711.20170031



INTRODUCTION

Central giant cell lesions (CGCLs) are rare benign intraosseous proliferative lesions that corresponds to fewer than 7% of all benign maxillary lesions. It is predominantly found in children and young adults, with 60% of cases occurring before age 30, and occurs more frequently in females and in the mandible^{1,2}.

Multinucleated giant cells are prominent throughout the fibroblastic stroma and are often clustered around areas of haemorrhage³. In radiographic images, CGCL may range from small apical lesions to large destructive multilocular radiolucencies involving large areas of the jaws².

CGCLs represent a treatment challenge. It's clinical behavior is extremely variable. Certain lesions are completely silent and grow very slowly whereas others are more aggressive, with pain, paresthesia, root resorption, rapid growth, cortical perforation, and a high recurrence rate⁴. In recurrent or aggressive lesions, en bloc resection, including healthy bone, is a treatment option, but it results in large surgical defects, which are undesirable in children or young adults. For the remaining lesions, the treatment indicated is simple curettage, curettage accompanied by peripheral osteotomy or cryotherapy with liquid nitrogen^{5,6}.

Surgical treatment is more difficult in patients with multiple lesions, because surgery may lead to extensive resection. In 1988, Jacoway et al.⁷ developed a nonsurgical approach, performed on an outpatient basis, that results in the resolution, or reduction in size, of the lesion and permits conservative removal with preservation of adjacent structures. It is referred as intralesional injection of corticosteroids⁶.

The technique is simple, low cost, relatively quick and avoids expressive aesthetic and functional defects. Corticosteroid therapy is, however, relatively contraindicated in certain medical conditions, such as diabetes mellitus, peptic ulcer, and generalized immunocompromised states^{6,8}.

On the basis of the experimental evidence, it is possible to hypothesize that the results obtained using intralesional steroids in the treatment of CGCLs of the jaw bones may be due to: inhibition of the extracellular production of lysosomal proteases; steroidal apoptotic action on osteoclast-like cells; or inhibition of transcription factors for intracellular proliferation. These three mechanisms cause cessation of resorption and improve bone regeneration and the recovery of normal function^{6,9}.

This paper aims to report a case of a pediatric patient with CGCL of the jaw, which was successfully treated with intralesional corticosteroid injections as it's only therapy and discuss if there is an ideal waiting period between nonoperative treatment and the need of surgical intervention.

CASE REPORT

An eight-year-old boy was referred to the Oral and Maxillofacial Surgery Service of a Public Hospital, in 2005, for the evaluation of swelling on the right side of his mandible. Patient noted no pain or paresthesia during the growth of the lesion.

On extraoral examination there was no clear asymmetry of the jaw. However, the intraoral inspection revealed a mild bulging in bottom lower right buccal vestibule in the region of the first permanent molar. The 45 and 47 dental units were in infraocclusion (Figure 1). There was no paresthesia or pain over the lower lip. Patient and their mothers' reported no history of local trauma.

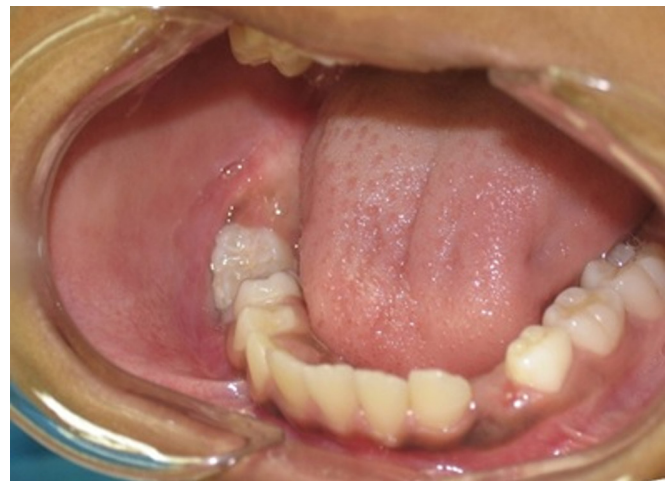

Figure 1. Intraoral examination revealed a mild bulging in bottom lower right buccal vestibule in the region of the first permanent molar and dental units 45 and 47 in infraocclusion.

Orthopantomograph (OPG) showed a well-circumscribed radiolucent image extending from the mandibular right parasymphysis to the mandibular right body, involving the roots of units 47 and 45 which was not fully formed (Figure 2A). The lesion measured 5x 2 cm in maximum dimensions on the OPG. Cortical expansion was observed in the occlusal radiography, with no evidence of fenestrations (Figure 2B). Incisional biopsy was performed and histological evaluation showed multinucleated giant cells surrounded by a disorganized

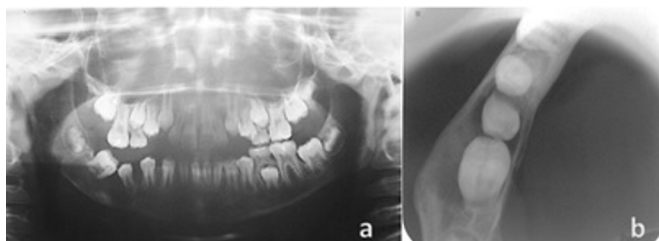


Figure 2. A) Orthopantomograph (OPG) showing a well-circumscribed radiolucent image measuring 5 x 2 cm in maximum dimensions, extending from the mandibular right parasymphysis to the mandibular right body and from alveolar crest to mandibular basis, involving roots of units 47 and 45 which are still not fully formed and causing deslocation of these teeth. B) Occlusal radiography showing cortical expansion due to lesion growth, but with no evidence of fenestrations.

stroma with hemorrhagic areas. Based on these characteristics, the final diagnosis was CGCL (Figure 3). Normal parathormone assay ruled out hyperparathyroidism.

Considering the age of the patient, intralesional steroid was the chosen therapy modality. Following the protocol outlined by Jacoway et al.⁷ local anesthesia was administered and a 1 ml for each 1 cm of the lesion, seen on the OPG, solution consisting of equal parts of triamcinolone actinide (10 mg/ml) and 0.5% bupivacaine was injected into the lesion by a disposable syringe. The applications were performed every week until the 8th week.

There was acceptance of the patient's responsible in relation to the proposed treatment protocol adopted, as well as authorization to be made photographic records and subsequent publication of the case in scientific literature as the regulations of the Ethics Committee of the Bahiana School of Medicine and Public Health, by signing the Instrument of Informed Consent (IC).

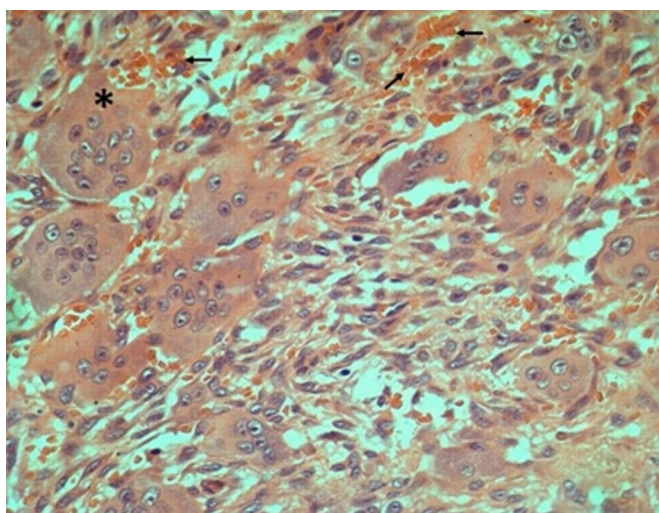


Figure 3. Microscopic aspect of the lesion illustrating clusters of giant cells (*) surrounded by spindle-shaped stromal cells. Hemorrhagic areas (h) visible in the vicinity of the giant cells. (Hematoxylin and eosin staining - Magnification 400X)

Shortly after the protocol infiltrations of triamcinolone, the patient did not return to the following appointment. Seven years have passed by since the first use of the drug and then, the patient returned to the department. Control examination showed a significant improvement of the clinical profile.

Patient had the intraoral swelling no longer. The crown of the unit 45 already had completely erupted and unit 47 was partly due to the mesioangulation of the tooth.

It was noted by the OPG that tooth roots were still in development stage, with apices still open. New bone formation in parasymphysis and mandibular body could be noticed and circumscribed radiolucent area, only associated with dental unit 47 root was still evident (Figure 4). At this point, surgical removal of the lesion was planned.

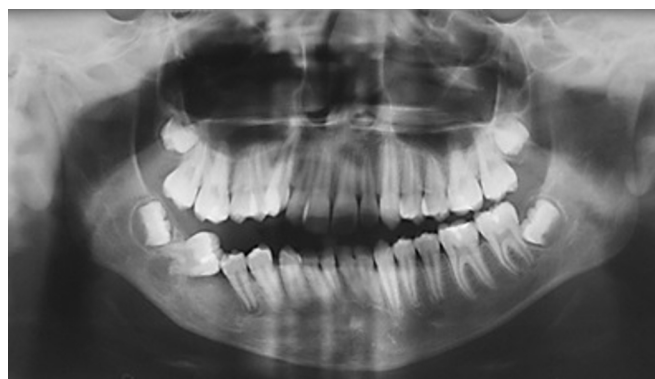

Figure 4. Seven years after corticoids injection, OPG presents tooth roots of units 45 and 47 were still in development stage, with apices open. New bone formation in parasymphysis and mandibular body can be noticed and circumscribed radiolucent area, only associated with the root of dental unit 47 still evident.

After one year without attending the service again, the patient returned to perform surgical approach. However, after a new radiographic control, there was complete regression of the lesion with evidence of new bone formation and complete root development of the 45 and 47 dental units and pulp vitality maintenance (Figure 5).

DISCUSSION

Central giant cell lesion is a non neoplastic lesion that may show aggressive clinical behavior. Chuong *et al.*⁴ differentiated between non-aggressive and aggressive lesions on the basis of signs and symptoms and histological features. The non-aggressive form is characterized by a slow, almost asymptomatic growth that does not perforate the cortical bone or induce root resorption and

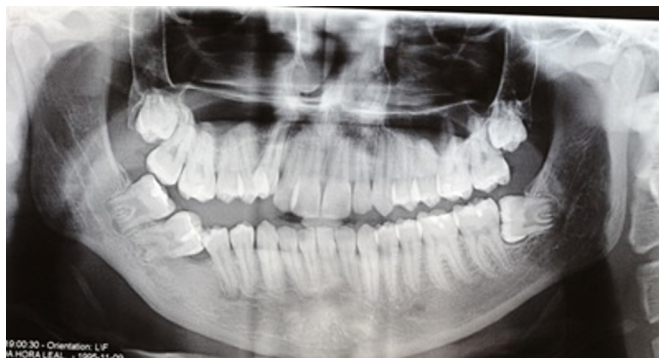

Figure 5. Eight-year radiographic control, showing regression of the lesion with evidence of new bone formation and complete root development of the 45 and 47 dental units.

has low recurrence rate. Aggressive lesions are characterized by one or more of the following features: large size (> 5 cm), pain, paresthesia, root resorption, rapid growth, cortical perforation and a high recurrence rate after surgical curettage. The case of the patient reported by us can be categorized as a non-aggressive form.

In conservative management various agents have been used with variable responses like intralesional steroids, systemic calcitonin (intralesional, subcutaneous) and intralesional interferon- α ¹⁰. The use of corticotherapy as an alternative therapeutic approach in the treatment of CGCL is already well established in the literature and as all treatment procedures has its advantages and disadvantages (Table 1).

For Bataineh *et al.*¹, nonsurgical treatment of CGCL is probably a good treatment option for small slowly enlarging lesions. Successful treatment of painful, large, and rapidly growing lesions is more likely achieved by surgical removal. Corroborating with these authors, Wendt *et al.*¹¹, in 2009, published a case report of an 8-year-old female patient with an asymptomatic

nodular lesion of approximately 1.5 cm in diameter in the anterior maxillary area. After incisional biopsy was conclusive for CGCL, Jacoway *et al.*⁷ protocol of triamcinolone administration was performed. After a 6-year follow-up period, the treatment was considered clinically and radiographically successful, demonstrated by the absence of radiolucent area without root divergence, complete root formation, and pulp vitality maintenance. This case described by Wendt *et al.*¹¹ is similar to the one reported in this article, which presents diameter of the lesion, treatment and results similarities.

Mohanty & Jhamb¹⁰, in 2009, studied a total of 15 cases report which were treated by intralesional corticosteroid. From the total of 15 cases, only 3 required surgical interventions for treatment of residual lesions. The authors did not mention the waiting period of action of the medication until the decision for surgical intervention.

Evaluating four patients, Carlos & Sedano⁹, in 2002, found that only 1 patient had a residual radiolucence of 0.5 cm, which was surgically treated by curettage. However, this patient underwent surgery only 15 months after the use of intralesional triamcinolone protocol, differing from other 3 cases described by the authors, where the average waiting time for determining the surgical approach was 3 years. Therefore we cannot determine whether a failure has occurred in the non-surgical treatment, or if the authors did not wait long enough for the complete regression of the lesion.

Another interesting factor reported by the authors⁸ was that histopathological exam obtained from the curetted lesion, showed few multinucleated giant cells in a fibrous-collagenous stroma, where there was a reduction of tissue vascularization. Corroborating with Mohanty & Jhamb¹⁰, who claim that the ossification de-

Table 1. Advantages and disadvantages of intralesional steroids use for CGCLs treatment.

Advantages	Disadvantages
1. Ease of administration and less invasive	1. Unpredictable response when compared to surgical option as the first choice
2. Relatively short duration of treatment (6 weeks average compared to 3 - 27 months for calcitonin and interferon-a)	2. Failure to target the prime neoplastic cells i.e. spindle shaped stromal cells.
3. Relatively higher success rate as compared to calcitonin /interferon- a	3. Healing occurs by fibrocollagenous tissue formation which later ossifies. This fibrous tissue may misguide the clinician as probable recurrence/ residual lesion
4. Cheaper	
5. Easily available	
6. Minimal systemic side effects	
7. No crippling effects on developing dentition	
8. The option to treat surgically or by other alternative conservative treatments in future if necessary	

velops from fibrous-collagenous tissue formation process, which may confuse the clinician with a process of recurrence or remaining residual lesion. It is suggested then that the patient surgically treated by Carlos & Sedano⁹ had its surgical therapy established hastily.

The authors⁸ also noted that the two pediatric patients, whom lesions were larger at the time of diagnosis and behaved more aggressively, responded to the treatment with a faster and better reparative reaction.

In 2012, Rachmiel et al.¹² described a combined treatment case report of an aggressive CGCL in the lower jaw. The first part of the treatment consisted in intralesional injections of triamcinolone associated with calcitonin nasal spray for 3 months. However, after three months following this medical protocol, although a decrease in tumor size was clinically observed, curettage and peripheral ostectomy with preservation of the continuity of the mandible and the teeth was performed. It was not possible for us to evaluate whether the lesion, even though presented aggressive behavior, would have complete regression and then, corroborated with Carlos & Sedano⁹.

Nogueira et al.⁶, in 2010, developed a study with 21 patients with CGCLs. They adopted as treatment protocol, intralesional injection of 20 mg/ml triamcinolone hexacetonide diluted in an anaesthetic solution infiltrated for every 1 cm³ of radiolucid area of the lesion, totaling 6 biweekly applications. Eight cases in 4-8 years of follow-up, exhibited complete regression of lesions without surgical intervention. Eleven patients were submitted to osteoplasty or curettage after intralesional injections. Only in two cases the lesion did not regress so the patients were treated conventionally by surgical resection.

Although the majority of the patients in this study⁶ were submitted to an additional procedure as osteoplasty and curettage, time between the end of infiltrations and the surgical procedures varied only from 3 to 12 months. This fact emphasizes that clinical cases with a higher follow-up period had less need for subsequent surgical procedures. In the present case a period of 7 years was not enough for the complete recovery of the injury, although 8 years was considered satisfactory.

Is there an ideal waiting period between non operative treatment and the need for surgical intervention? In the case reported in this paper, after seven years there was still radiographic evidence of the lesion. Despite this, only one year after (eight years of follow-up) this picture had changed, the lesion regressed. There with, one can assume that the noninvasive treatment of CGCLs requires a long period of monitoring to determinate treatment success.

An average of 3 years of waiting was described in various reports cited in this paper. However, it was observed that cases of lengthy delays generally required no additional surgical intervention for the definitive treatment of CGCLs.

The outcome of the monitoring of this case suggests that the period of three years is insufficient for the regression of those nonsurgical treatment cases. It is estimated that a monitoring period of 6-8 years is necessary to determine the success of such treatment. More clinical cases with long-term follow-ups must be reported in the literature in order to establish a protocol for a minimum follow-up period for the treatment with intralesional corticosteroids.

REFERENCES

1. Bataineh AB, Al-Khateeb T, Rawashdeh MA. The surgical treatment of central giant cell granuloma of the mandible. *J Oral Maxillofac Surg.* 2002;60:756-61.
2. De Lange J, Van den Akker HP. Clinical and radiological features of central giant-cell lesions of the jaw. *Oral Surg Oral Med Oral Pathol Oral Radiol Endod.* 2005;99:464-70.
3. de Lange J, van den Akker HP, van den Berg H. Central giant cell granuloma of the jaw: a review of the literature with emphasis on therapy options. *Oral Surg Oral Med Oral Pathol Oral Radiol Endod.* 2007;104:603-15.
4. Chuong R, Kaban LB, Kozakewich H, Perez-Atayde A. Central giant cell lesions of the jaws: a clinicopathologic study. *J Oral Maxillofac Surg.* 1986;44:708-13.
5. Nicolai G, Lorè B, Mariani G, Bollero P, de Marinis L, Calabrese L. Central giant cell granuloma of the jaws. *J Craniofac Surg.* 2010;21:383-6.
6. Nogueira RLM, Teixeira RC, Cavalcante RB, Ribeiros RA, Rabenhosr SH. Intralesional injection of triamcinolone hexacetonide as an alternative treatment for central giant-cell granuloma in 21 cases. *Int J Oral Maxillofac Surg.* 2010;39:1204-10.
7. Jacoway JR, Howell FV, Terry BC. Central giant cell granuloma: an alternative to surgical therapy. *Oral Surg Oral Med Oral Pathol.* 1988;66:572.
8. Sezer B, Koyuncu B, Gomel M, Günbay, T. Intralesional corticosteroid injection for central giant cell granuloma: a case report and review of the literature. *Turk J Pediatr.* 2005;47:75-81.
9. Carlos R, Sedano HO. Intralesional corticosteroids as an alternative treatment for central giant cell granuloma. *Oral Surg Oral Med Oral Pathol Oral Radiol Endod.* 2002;93:161-6.
10. Mohanty S, Jhamb A. Central giant cell lesion of mandible managed by intralesional triamcinolone injections. A report of two cases and literature review. *Med Oral Patol Oral Cir Bucal.* 2009;14:E98-102.
11. Wendt FP, Torriani MA, Gomes AP, de Araujo LM, Torriani DD. Intralesional corticosteroid injection for central giant cell granuloma: an alternative treatment for children. *J Dent Child (Chic).* 2009;76:229-32.
12. Rachmiel A, Emodi O, Sabo E, Aizenbud D, Peled M. Combined treatment of aggressive central giant cell granuloma in the lower jaw. *J Craniomaxillofac Surg.* 2012;40:292-7.