








Marcelo Santos Bahia^{1*} 
 Yuri de Lima Medeiros² 
 Maria Emilia Mota² 
 Marcella Yumi Kadooka¹ 
 Pablo Agustin Vargas³ 
 Cassio Edvard Sverzut¹ 
 Alexandre Elias Trivellato¹ 

Odontogenic onset mucormycosis in a post-COVID-19 diabetic patient: an unusual report

Abstract:

Fungal infections associated with COVID-19 have been responsible for exacerbating the course of the disease, with mucormycosis being one of the main reported conditions. Although dental involvement is commonly considered an extension of rhinocerebral disease, some authors recognize it as a distinct clinical entity characterized by odontogenic onset mucormycosis. The aim of this study was to report the diagnosis of mucormycosis following drainage of odontogenic abscess in a post-COVID-19 diabetic patient. A 69-year-old post-COVID-19 diabetic man sought a maxillofacial surgery service due to complaints of pain and swelling on the right side of the face. Edema, dental mobility, and purulent discharge associated with teeth 16 and 17 were noted. It was observed that tooth 16 had undergone endodontic treatment, while tooth 17 exhibited pulp necrosis, both showing enlargement of the apical periodontal ligament space. Drainage of the odontogenic abscess was performed, and cone-beam computed tomography was requested. Tomographic findings included a suggestive image of osteolytic lesion in the posterior region of the maxilla extending into the right maxillary sinus. Extraction of teeth 16 and 17 and biopsy of areas of necrotic bone were performed. Histopathological examination revealed numerous large fungal hyphae forming right angles, positive for Grocott-Gomori staining, favoring the diagnosis of mucormycosis. The patient was referred for treatment with Amphotericin B and has been under follow-up for 3 years, with no need for additional interventions. The diagnosis of mucormycosis should be considered in immunosuppressed patients, especially those with diabetes mellitus and post-COVID-19, presenting signs and symptoms of odontogenic infection.

Keywords: Mucormycosis; Diabetes mellitus; COVID-19; Tooth abscess.

INTRODUCTION

In March 2020, COVID-19, the disease caused by the new coronavirus SARS-COV-2, was declared a pandemic by the World Health Organization (WHO). Even though mortality rates were drastically reduced after vaccination campaigns, there are more than 774 million cases reported and 7 million notified deaths worldwide¹. Due to

pulmonary damage, immune system dysregulation and immunosuppressive therapies used in its treatment,

this condition is associated with a wide spectrum of diseases, increasing its susceptibility to secondary bacterial and fungal infections^{2,3}. Among the fungal infections, aspergillosis, candidiasis, cryptococcosis and mucormycosis stand out².

Mucormycosis is a fatal and rare opportunist infection, usually caused by the *Rhizopus spp* gender,

Statement of Clinical Significance

The early recognition of mucormycosis in post-COVID-19 diabetic patients presenting with odontogenic infections is crucial for reducing mortality. This report highlights the need for prompt diagnosis and treatment in immunosuppressed individuals, emphasizing the importance of histopathological confirmation and interdisciplinary management in such cases.

¹University of São Paulo, School of Dentistry of Ribeirão Preto, Department of Oral and Maxillofacial Surgery and Periodontology – Ribeirão Preto (SP), Brazil.

²São Paulo University, School of Dentistry, Department of Stomatology – São Paulo, SP, Brazil.

³University of Campinas, Piracicaba Dental School, Oral Diagnosis Department – Piracicaba (SP), Brazil.

*Correspondence to: Email: marcelosbahia@usp.br

Received on October 22, 2024. Accepted on November 13, 2024.

<https://doi.org/10.5327/2525-5711.269>



responsible for almost 60% of the cases. This disease affects specially immunosuppressed patients, commonly associated with hematological malignant neoplasms and organ transplant⁴⁻⁶. Furthermore, diabetes mellitus is one of the main risk factors for mucormycosis, resulting from reduced glycemic control and increased rate of fungal infiltration due to diabetic ketoacidosis⁴. Most common clinical aspects of mucormycosis include the involvement of paranasal sinuses and lungs. Colonization of the oral microbiota by the fungus in susceptible individuals is common and can generate odontogenic symptoms, such as tooth mobility, abscess, osteomyelitis and purulent secretion⁷⁻⁹. Although commonly considered to be extensions of sinus disease, Manesh et al.⁸ recognize them as a distinct clinical entity, characterizing them as mucormycosis with an odontogenic onset. The aim of this study was to report the diagnosis of mucormycosis following drainage of odontogenic abscess in a post-COVID-19 diabetic patient.

CASE REPORT

A 69-year-old male attended the Oral and Maxillofacial Surgery service of the School of Dentistry of Ribeirão Preto, University of São Paulo (Ribeirão Preto, Sao Paulo, Brazil), complaining of volume increase and continuous pain in the left face area for the last seven days. He reported having type 2 diabetes mellitus and a COVID-19 diagnosis a month ago. He was hospitalized for eight days for the symptomatic treatment of the disease and subsequent worsening of the condition, having been submitted to orotracheal intubation and daily use of Rivaroxaban. He was then referred for our service due to dental mobility of the right upper molars. The patient was also previously medicated with Amoxicillin 500 mg due to the infection process hypothesis.

During the extraoral exam, we observed mouth-opening limitation and facial asymmetry in the right malar region, with volume increase extending it from the infraorbital margin until the anteroposterior zygomatic bone and from the eye medial canthus until the nose alar base from the right side. Volume increase presented a softened aspect, pain during palpation, associated with erythema and local heat, and discreet point of fluctuation. The intraoral exam revealed a volume increase in the fundus of the maxillary vestibular sulcus and purulent discharge associated with the upper molars. The upper right first and second molars presented

mobility grade 3 and pain during vertical and horizontal percussion. Tooth 16 showed signs of previous endodontic treatment, while tooth 17 exhibited pulp necrosis. Both teeth demonstrated an enlargement of the apical periodontal ligament space (Figure 1).

The surgical drainage of the odontogenic abscess was performed, with the installation of a Penrose drain followed by antibiotic prescription with Amoxicillin/Clavulanate Potassium 875 mg+125 mg for 7 days, Ketoprofen 100 mg for 03 days and Dipyron 500mg in case of pain. We requested a cone-beam computed tomography scan (CBCT scan) for the extraction planning, and we noticed a suggestive image of an osteolytic lesion in the posterior maxillary region extending to the right maxillary sinus (Figure 2).

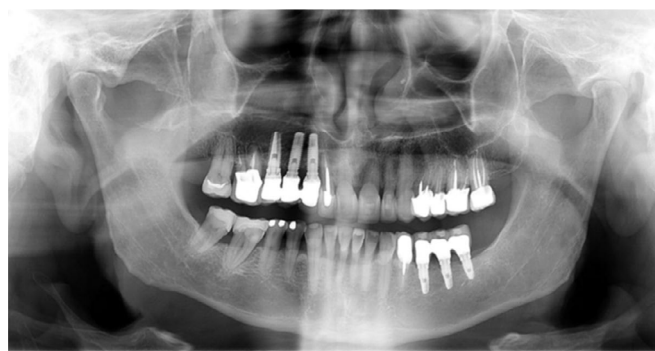

Figure 1. Panoramic radiography.

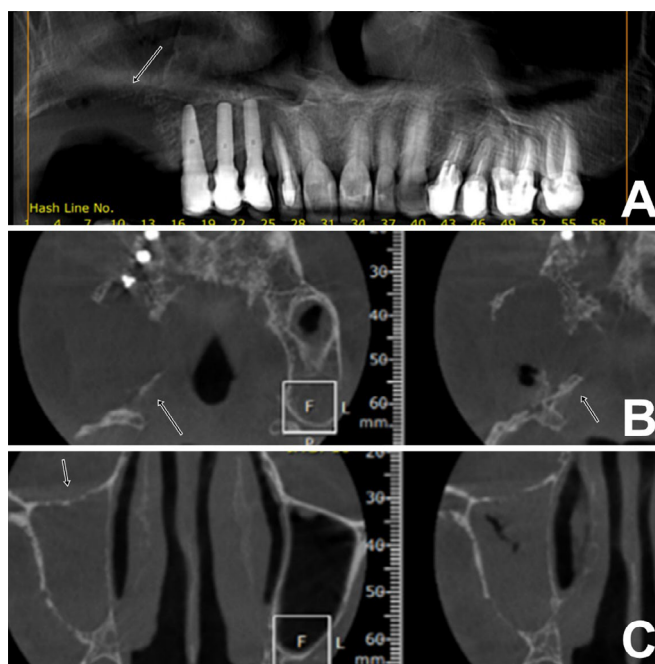


Figure 2. Cone-beam computed tomography displaying an osteolytic lesion (arrows) in the posterior maxillary region extending to the right maxillary sinus.

DISCUSSION

The upper right first and second molars, in poor condition with extensive restorations, were extracted. Necrotic bone tissue fragments, ranging from 6 to 14 mm in greatest dimension, were subsequently removed and submitted for histopathological analysis (Figure 3).

Histopathological examination revealed necrotic bone trabeculae interspersed with numerous large fungal hyphae forming right angles (Figure 4), positive for Grocott-Gomori staining (Figure 5), and the presence of neutrophilic inflammatory infiltrate. The clinical and microscopic image aspects favoured the diagnosis of mucormycosis of the right maxilla. The patient was referred to an infectious disease specialist and underwent intravenous liposomal amphotericin B treatment for 30 days. Currently, the patient has been under follow-up for 3 years, showing progressive improvement and stabilization of the condition, with no need for additional interventions.

Mucormycosis affects patients with different levels of immune impairment, especially those in tropical and subtropical climate zones¹⁰. Its diagnosis is extremely relevant due to the risk of rapid progression and high mortality¹¹, evidenced in cases associated with COVID-19, especially in the presence of other systemic diseases such as diabetes mellitus¹². We report the diagnosis of mucormycosis after drainage of an odontogenic abscess in a post-COVID-19 diabetic patient, indicating a possible odontogenic onset of the infection.

Following the declaration of the COVID-19 pandemic in 2020, patients requiring invasive ventilation in intensive care units were frequently diagnosed with fungal co-infections¹³. Among these, those caused by *Aspergillus*, *Candida* and *Mucorales* species stood out¹⁴. Since then, there has been interest in understanding the immunopathogenesis of this association, which is not yet completely understood but involves multiple factors^{15,16}. It is known that SARS-CoV-2 infection alters individuals' immune and metabolic responses, producing an inflammatory environment that promotes infection¹⁴. Furthermore, the treatment of COVID-19 with corticosteroids has been associated with an increased risk of fungal infections due to their immunosuppressive properties⁴. A systematic review showed that corticosteroids were administered in 76.3% of cases of Mucormycosis in patients with COVID-19¹⁷. The immunosuppression caused by prolonged use of these medications also has the adverse effect of

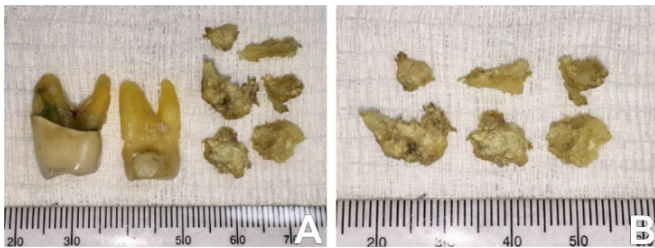


Figure 3. (A) Extracted right maxillary first and second molars in poor condition, exhibiting extensive restorations. (A-B) Fragments of necrotic bone tissue, ranging from 6 to 14 mm in greatest dimension, removed and sent for histopathological analysis.

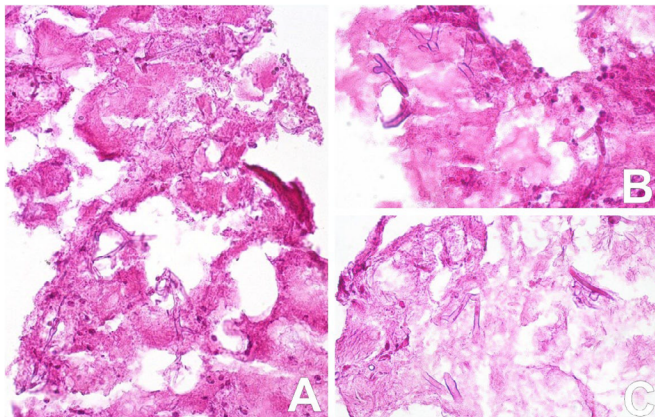


Figure 4. Histological examination of a sample of tissue from the maxilla, which was stained using hematoxylin and eosin (H&E), displayed an inflammatory infiltrate predominantly consisting of neutrophils. The assessment was conducted at 200x magnification for (A) and 400x magnification for (B) and (C). The clinical, radiographic, and microscopic characteristics align with the diagnosis of maxillary mucormycosis, indicating a significant presence of neutrophilic cells infiltrating the impacted tissue.

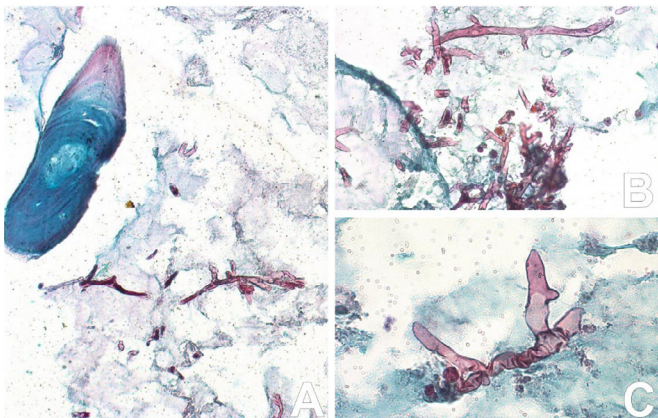


Figure 5. Histopathological analysis of curettage-derived fragments, revealing bone trabeculae with intercalated necrosis by numerous large fungal hyphae, forming right angles and positive for Grocott-Gomori staining. Confirmation of mucormycosis diagnosis. (A) 200x magnification, (B) 400x magnification, and (C) Immersion magnification.

steroid-induced diabetes, which further exacerbates the patient's susceptibility to infections⁴.

On the other hand, diabetes is a metabolic disease resulting from a deficiency in insulin secretion or action, which increases the frequency and severity of infectious diseases¹⁶. A recent retrospective study demonstrated that patients with diabetes had risk factors that affected the COVID-19 prognosis, such as levels of glucose, C-reactive protein, procalcitonin, creatinine, total bilirubin, and plasma D-dimer¹⁸. Additionally, a recent systematic review included 958 adults who developed mucormycosis during or after COVID-19. It was observed that diabetes was the most common comorbidity related to this infection, being only 5.7% in the post-COVID period, such as in our case¹².

Extraoral signs of mucormycosis include headaches and sinus pain, congestion and bloody nasal discharge, fever, and facial edema. It also usually precedes oral manifestations, which occur after 1-2 weeks and consist of exposed bone and ulcers¹⁸. In our case, we initially observed facial oedema associated with erythema and local heat, with a slight floating point in addition to purulent secretion associated with the upper molars. Tooth mobility and alveolar osteomyelitis are also signs already associated with this infection. However, other authors report cases of mucormycosis of the paranasal sinuses of odontogenic origin after COVID-19 in 6 patients. All patients had uncontrolled diabetes and showed signs of infection in the oral cavity, and 3 had tooth mobility, such as in our case. Spontaneous tooth loss has also been reported⁹.

Afterwards, Manesh et al.⁸ suggested that the odontogenic association with mucormycosis is a new entity of this infection, which arises precisely from the oral cavity, particularly from the alveolar bone, reporting a prevalence of 8.2% of mucormycosis evaluated cases. In this study, the most common symptoms were tooth pain and mobility (100%), facial oedema (66.7%) and purulent secretion (28.6%), all symptoms observed in our case. However, future epidemiological studies are required for a better understanding of the association of odontogenic infection foci with mucormycosis and the etiopathogenesis of this possible entity.

The precocious diagnosis of mucormycosis is essential and reduces the disease's high mortality rate. The gold standard is biopsy and histopathological analysis, characterized by mucorales, which appear as strip-shaped hyaline filaments and hyphae with variable diameters. Furthermore, calcofluor-white is indicated when there is little sample available, and the polymerase

chain reaction (PCR) is used to complement the histopathological diagnosis¹⁹. Culture is also recommended for identifying species and carrying out antifungal susceptibility testing²⁰. The infection treatment mostly consists of liposomal amphotericin B administration, which often requires months of therapy^{19,20}. Furthermore, in most cases, patients require oral rehabilitation due to extensive defects caused by the infection¹⁹.

CONCLUSION

The diagnosis of mucormycosis should be considered in immunosuppressed patients, especially those with diabetes mellitus and post-COVID-19 presenting signs and symptoms of odontogenic infection.

ACKNOWLEDGEMENTS

The authors would like to thank Alexander Tadeu Sverzut "*In memoriam*" for help in editing this manuscript.

AUTHORS' CONTRIBUTIONS

MSB: conceptualization, data curation, investigation, methodology, writing – original draft. YLM: data curation, methodology, writing – original draft. MEM: data curation, methodology, writing – original draft. MYK: data curation, resources, writing – original draft. PAV: formal analysis, investigation, resources, validation, visualization, writing – review & editing. CES: conceptualization, investigation, supervision, visualization, writing – review & editing. AET: conceptualization, formal analysis, investigation, methodology, project administration, supervision, visualization, writing – review & editing.

CONFLICT OF INTEREST STATEMENT

Funding: The authors declare that no funds, grants, or other support were received during the preparation of this manuscript.

Competing interests: The authors have no relevant financial or non-financial interests to disclose.

Ethics approval: All procedures performed in studies involving human participants were in accordance with the ethical standards of the institutional and national research committee and with the 1964 Helsinki declaration and its later amendments or comparable ethical standards. Informed consent was obtained from the patient.

REFERENCES

1. World Health Organization. Coronavirus disease (COVID-19) epidemiological updates and monthly operational updates [Internet]. Geneva: World Health Organization, 2024 [accessed in July 20, 2024]. Available from: <https://www.who.int/emergencies/diseases/novel-coronavirus-2019/situation-reports>
2. Naveen KV, Saravanakumar K, Sathiyaseelan A, MubarakAli D, Wang MH. Human fungal infection, immune response, and clinical challenge-a perspective during COVID-19 pandemic. *Appl Biochem Biotechnol.* 2022;194:4244-57. <https://doi.org/10.1007/s12010-022-03979-5>
3. Tayabali K, Pothiwalla H, Narayanan S. Epidemiology of COVID-19-associated mucormycosis. *Curr Fungal Infect Rep.* 2023;1-20. <https://doi.org/10.1007/s12281-023-00464-2>
4. Dwivedi S, Choudhary P, Gupta A, Singh S. The cross-talk between mucormycosis, steroids and diabetes mellitus amidst the global contagion of COVID-19. *Crit Rev Microbiol.* 2023;49(3):318-33. <https://doi.org/10.1080/1040841X.2022.2052795>
5. John TM, Jacob CN, Kontoyiannis DP. When uncontrolled diabetes mellitus and severe covid-19 converge: the perfect storm for mucormycosis. *J Fungi (Basel).* 2021;7(4):298. <https://doi.org/10.3390/jof7040298>
6. Sengupta I, Nayak T. Coincidence or reality behind Mucormycosis, diabetes mellitus and Covid-19 association: a systematic review. *J Mycol Med.* 2022;32(3):101257. <https://doi.org/10.1016/j.mycmed.2022.101257>
7. Janjua OS, Shaikh MS, Fareed MA, Qureshi SM, Khan MI, Hashem D, et al. Dental and Oral Manifestations of COVID-19 related mucormycosis: diagnoses, management strategies and outcomes. *J Fungi (Basel).* 2021;8(1):44. <https://doi.org/10.3390/jof8010044>
8. Manesh A, Devasagayam E, Sahu S, Bhanuprasad K, Mannam P, Karthik R, et al. Primary odontogenic onset invasive mucormycosis-an under recognized clinical entity. *Clin Microbiol Infect.* 2023;29(8):1086.e1-1086.e5. <https://doi.org/10.1016/j.cmi.2023.05.002>
9. Saidha PK, Kapoor S, Das P, Gupta A, Kakkar V, Kumar A, et al. Mucormycosis of paranasal sinuses of odontogenic origin post COVID19 infection: a case series. *Indian J Otolaryngol Head Neck Surg.* 2022;74(Suppl 2):3437-41. <https://doi.org/10.1007/s12070-021-02638-1>
10. Gupta I, Baranwal P, Singh G, Gupta V. Murcomycosis, past and present: a comprehensive review. *Future Microbiol.* 2023;18:217-34. <https://doi.org/10.2217/fmb-2022-0141>
11. Petrikkos G, Skiada A, Lortholary O, Roilides E, Walsh TJ, Kontoyaiannis DP. Epidemiology and clinical manifestations of murcomycosis. *Clin Infect Dis.* 2012;54 Suppl 1:S23-34. <https://doi.org/10.1093/cid/cir866>
12. Ozbek L, Topçu U, Many M, Esen BH, Bektas SN, Aydin S, et al. COVID-19-associated murcomycosis: a systematic review and meta-analysis of 958 cases. *Clin Microbiol Infect.* 2023;29(6):722-31. <https://doi.org/10.1016/j.cmi.2023.03.008>
13. Centers for Disease Control and Prevention. Fungal diseases and COVID-19 [Internet]. 2020 [accessed in June 15, 2024]. Available from: <https://www.cdc.gov/fungal/hcp/covid-fungal/index.html#:~:text=COVID%2D19%20likely%20increases%20the,the%20body's%20defenses%20against%20fungi>
14. Hoenigl M., Seidel D, Sprute R, Cunha C, Oliverio M, Goldman GH, et al. COVID-19-associated fungal infections. *Nat Microbiol.* 2022;7(8):1127-40. <https://doi.org/10.1038/s41564-022-01172-2>
15. Salazar F, Bignell E, Brown GD, Cook PC, Warris A. Pathogenesis of respiratory viral and fungal coinfections. *Clin Microbiol Rev.* 2022;35(1):e0009421. <https://doi.org/10.1128/CMR.00094-21>
16. Heshmati HM. Interactions between COVID-19 infection and diabetes. *Front Endocrinol (Lausanne).* 2024;14:1306290. <https://doi.org/10.3389/fendo.2023.1306290>
17. Singh AK, Singh R, Joshi SR, Misra A. Mucormycosis in COVID-19: a systematic review of cases reported worldwide and in India. *Diabetes Metab Syndr.* 2021;15(4):e102146. <https://doi.org/10.1016/j.dsx.2021.05.019>
18. Sun L, Yang X, Cao B, Su X, Wang J, Xu C. Retrospective study of the impact of diabetes on the severity and prognosis of COVID-19. *Exp Ther Med.* 2024;27(5):194. <https://doi.org/10.3892/etm.2024.12482>
19. Mora-Martinez A, Murcia L, Rodríguez-Lozano FJ. Oral manifestations of mucormycosis: a systemic review. *J Fungi (Basel).* 2023;9(9):935. <https://doi.org/10.3390/joe9090935>
20. Cornely OA, Alastruey-Izquierdo A, Arenz D, Chen SCA, Dannaoui E, Hochhegger B, et al. Global guideline for the diagnosis and management of murcomycosis: an initiative of the European Confederation of Medical Mycology in cooperation with the Mycoses Study Group Education and Research Consortium. *Lancet Infect Dis.* 2019;19(12):e405-e421. [https://doi.org/10.1016/s1473-3099\(19\)30312-3](https://doi.org/10.1016/s1473-3099(19)30312-3)