
















Allergic contact stomatitis associated with toothpaste use in Brazil: a multicenter retrospective case series

Breno Amaral Rocha^{1,2} , Guilherme Veloso Ramos¹ , Lilian de Barros¹ , Giovanna Ribeiro Souto¹ , Soraya de Mattos Camargo Grossmann¹ , Paulo Eduardo Alencar Souza¹ , Rodrigo Villamarim Soares¹ , Alan Roger Santos-Silva³ , Marcio Ajudarte Lopes³ , Thaís Cristina Esteves-Pereira³ , Maria Cássia Ferreira de Aguiar⁴ , Hyago Portela Figueiredo⁴ , Rafael Aguiar de Sousa⁴ , João Adolfo Costa Hanemann⁵ , Martinho Campolina Rebello Horta^{1*} 

Abstract:

Objective: This study describes the clinical features and outcomes of Brazilian patients diagnosed with suspected allergic contact stomatitis (ACS) after using a newly introduced commercial toothpaste formulation. **Methods:** This multicenter retrospective case series included six patients evaluated between January and May 2025 by Oral Medicine services at four universities. Inclusion criteria comprised clinical signs and/or symptoms compatible with ACS, recent use of a new Colgate-Palmolive toothpaste formulation containing stannous fluoride, and no reported exposure to other allergens. Clinical data retrieved from patient records underwent descriptive analysis. **Results:** All patients presented acute oral symptoms including burning, pain, dysphagia, and dyslalia. Clinical signs included erythematous macules, white plaques, desquamation, vesicles, erosions and ulcers affecting different oral sites. Lesions resolved within 4 to 29 days after toothpaste discontinuation, with or without pharmacologic intervention. No cases required biopsy or patch testing. In all cases, the temporal relationship and remission following toothpaste withdrawal supported the diagnosis of ACS. **Conclusions:** This study highlights a potential association between toothpaste formulations and ACS. Given the complexity of toothpaste formulations and the absence of allergological testing, the causative substance remains uncertain. Clinicians should consider ACS in patients presenting with unexplained oral lesions and recent changes in oral hygiene products.

Keywords: Toothpastes; Hypersensitivity; Mouth mucosa; Oral medicine; Public health.

INTRODUCTION

Allergic contact stomatitis (ACS) (i.e., oral hypersensitivity reaction, oral contact allergy) is a relatively uncommon immunoinflammatory lesion of the oral mucosa, triggered by an antigen-specific T cell-mediated hypersensitivity reaction to exogenous allergens in contact with this mucosal membrane. Patients may present signs as erythema, desquamation, white patches and plaques, vesicles, erosions, ulcers, edema, cheilitis and perioral dermatitis, in addition to symptoms such as burning sensation, pain, itchiness, dysgeusia, dysphonia and difficulty in mastication, which can decrease their quality of life. The clinical manifestations usually resolve

Statement of Clinical Significance

Brazil recently faced oral reactions following the use of a newly introduced commercial toothpaste formulation. This multicenter retrospective case series study describes Brazilian patients diagnosed with suspected allergic contact stomatitis after using the new Colgate-Palmolive toothpaste formulation containing stannous fluoride.

gradually after removal of the causative allergen¹⁻⁴. According to the American Academy of Oral Medicine (AAOM), this disorder may be associated with dental materials (e.g., amalgam, resins, acrylics and metals), as well as substances found in common food items (e.g.,

¹Pontifícia Universidade Católica de Minas Gerais, Graduate Program in Dentistry – Belo Horizonte (MG), Brazil.

²Afya Centro Universitário, Department of Dentistry – Montes Claros (MG), Brazil.

³University of Campinas, Dental School, Oral Diagnosis Department – Piracicaba (SP), Brazil.

⁴Federal University of Minas Gerais, School of Dentistry, Department of Oral Pathology and Surgery – Belo Horizonte (MG), Brazil.

⁵Federal University of Alfenas School of Dentistry – Alfenas (MG), Brazil.

*Correspondence to: E-mail: martinohorta@pucminas.br

Received on October 13, 2025. Accepted on February 9, 2026.

https://doi.org/10.5327/2525-5711.433



flavoring agents as cinnamon and spearmint), oral hygiene products (e.g., essential ingredients of toothpastes and mouth rinses) and topically applied medications².

Brazil faced, especially in the first semester of 2025, a significant number of complaints concerning oral mucosal adverse effects, possibly related to the use of a traditional commercial toothpaste brand. According to a technical alert of the Brazilian Health Regulatory Agency (Anvisa), published in March 2025, a growing pattern of adverse reactions to toothpastes containing stannous fluoride has been shown by official cosmetovigilance data, combined with reports displayed on social media, registered on consumer complaint platforms and published by the national media⁵.

In this context, on March 27, 2025, Anvisa published a resolution for the precautionary interdiction of all batches of the Colgate Total Clean Mint[®] toothpaste manufactured by Colgate-Palmolive⁶. In an official statement, Anvisa reported that this regulatory action was due to a significant number of adverse effects associated with the use of Colgate Total Prevenção Ativa[®], a toothpaste commercially launched in Brazil in 2024, featuring a new formulation containing stannous fluoride. The agency detected an increasing rate of adverse events of the new formulation, compared to the previous formula, such as oral lesions, pain, burning/stinging sensations, gingival inflammation and lip edema. According to Anvisa, the precautionary interdiction is a preventive and temporary measure to protect public health, and it remains in effect while the tests, evidence, analyses, or other procedures required for the investigation and conclusion of the case are carried out. Therefore, the product should not be used or sold until its safety has been proven⁷.

Later on the same date, in a press release widely circulated by the Brazilian national media, Colgate-Palmolive reiterated its commitment to the quality and safety of its products and informed that it was aware of Anvisa's decision, which did not entail a product recall. The manufacturer also reported that, after filing an appeal, the interdiction of the Colgate Total Clean Mint[®] toothpaste had been automatically suspended, and emphasized the continuation of all appropriate measures to interact with Anvisa and to demonstrate the product's safety. Finally, the company stated that the product does not pose health risks to consumers, even though some people may present sensitivity to certain ingredients, such as stannous fluoride, dyes or flavors^{8,9}.

Afterward, on April 30, 2025, Anvisa reported that the appeal with suspensive effect had been withdrawn

by the manufacturer and, as a result, the product's precautionary interdiction became valid again¹⁰. The manufacturer, in another press release, stated that the decision to withdraw the appeal was motivated by its ongoing cooperation with Anvisa and by the progress of the agency's technical investigations^{11,12}.

Finally, on June 25, 2025, Colgate-Palmolive officially announced the discontinuation of the Colgate Total Prevenção Ativa Clean Mint[®] toothpaste in Brazil. According to the manufacturer's communication, the toothpaste did not present quality problems, and this decision was prompted by an investigation conducted with attention to Brazilian consumers and Anvisa, focusing on the product's flavoring levels. The company also warned consumers that if they noticed any discomfort, irritation or unusual changes while using the product, they should immediately discontinue its use and contact their dentist¹³⁻¹⁵.

In the following days, health alerts regarding the new formulation of Colgate-Palmolive toothpaste containing stannous fluoride were issued by other Latin American countries¹⁶⁻²¹. On July 22, 2025, the use, distribution, and commercialization of the product were prohibited by the health surveillance authority in Argentina, after notifications of suspected adverse reactions^{16,17}. In Colombia, after a meeting with the sanitary authorities, who had received reports of possible adverse effects, the company decided to discontinue the product's commercialization on July 25, 2025^{16,18}. After suspected adverse reaction reports in Chile and following a joint analysis with public health authorities, the manufacturer voluntarily decided to remove the toothpaste from the market on July 31, 2025^{16,19}. In Mexico, in response to reports of potential adverse effects, sanitary authorities instructed the company to withdraw the toothpaste from the market on August 4, 2025^{16,20,21}.

From this perspective, this multicenter retrospective case series describes the clinical features and outcomes of six Brazilian patients diagnosed in 2025 with suspected ACS following the use of a newly introduced Colgate-Palmolive toothpaste formulation containing stannous fluoride.

MATERIAL AND METHODS

This multicenter retrospective case series was carried out by Oral Medicine services at four Brazilian universities. The study was conducted in accordance with the Strengthening the Reporting of Observational Studies in Epidemiology (STROBE) checklist.

Written informed consent was obtained from all study participants in accordance with the Declaration of Helsinki. This multicenter study was approved by the Ethical Research Committees at the Pontifícia Universidade Católica de Minas Gerais (PUC Minas) (CAAE: 88903725.7.3003.5137), at the Piracicaba Dental School, University of Campinas (FOP-UNICAMP) (CAAE: 88903725.7.0000.5418), at the Federal University of Minas Gerais (UFMG) (CAAE: 88903725.7.3002.5149) and at the Federal University of Alfenas (UNIFAL) (CAAE: 88903725.7.3001.5142).

The following inclusion criteria were used:

1. Brazilian patients clinically evaluated between January and May 2025;
2. Patients who presented signs and/or symptoms compatible with ACS;
3. Patients who reported using the new Colgate-Palmolive toothpaste formulation containing stannous fluoride, prior to the onset of signs and/or symptoms;
4. Patients with no evidence of oral contact with other allergens (information based on the patient's report).

The following clinical-pathological and demographic data were collected from clinical records: sex, age, city and state, specific toothpaste brand used, clinical history, oral examination findings, interventions, outcomes, diagnosis (tentative/final).

Descriptive data analysis was performed using Microsoft Office Excel® (Microsoft, Redmond, WA, USA).

RESULTS

An overview of the clinical-pathological and demographic data of the six reported cases is provided in Table 1. A detailed description of each case is presented below.

Case 1

On March 14, 2025, a 66-year-old female patient sought for private dental care in the city of Belo Horizonte (MG), complaining of oral burning, dry lips, and red spots in the mouth. The patient reported that, approximately 3 months earlier, she had started using the new Colgate Total Prevenção Ativa® toothpaste. After a few days of starting the product's use, the patient reported discomfort, dryness, and roughness in the lower labial mucosa and mandibular vestibule, burning in the upper labial mucosa and gingival erythema with burning sensation. She also described severe oral burning sensation

during and after brushing teeth with the toothpaste. Intraoral examination revealed enanthema on the oral mucosa, characterized by: desquamative gingivitis, with areas of erythema and erosion in the vestibular gingiva, between the right and left premolars, in the lower and upper arches, more evident in the mandibular arch (Figure 1A, 1C, and 1E); poorly delimited erythematous macules, occasionally related to punctiform ulcers and erosions, located on the inferior oral vestibule adjacent to teeth 33, 34, and 35 (Figure 1C), and also located bilaterally on the upper labial mucosa adjacent to buccal mucosa (Figure 1E and 1G). The following diagnostic hypotheses were considered: mucocutaneous autoimmune diseases and ACS to toothpaste. The patient was advised to immediately replace the toothpaste with a different one. Oral prednisone (20 mg/day for 5 days) was also prescribed. Two days after the initial consultation, the patient reported a significant reduction in the burning sensation. After two additional days, she observed complete remission of the oral lesions. At a follow-up appointment, 10 days after the toothpaste replacement, no symptoms and no oral mucosal lesions were detected (Figure 1B, 1D, 1F and 1H), supporting the diagnosis of ACS to toothpaste. Throughout the patient's care, the private dentist received remote guidance from the Oral Medicine Service of the Department of Dentistry at PUC Minas.

Case 2

On April 14, 2025, a 11-year-old female patient sought for private dental care in the city of Patos de Minas (MG), showing severe pain and burning in the tongue, dysphagia and dyslalia. About 5 days earlier, before the onset of these symptoms, the patient had started using the new Colgate Total Prevenção Ativa Antitártaro® toothpaste. The physical examination showed multiple thick white plaques on the ventral surface and lateral borders of the tongue, bilaterally, associated to small areas of erythema (Figure 2A and 2D). Although not completely detachable, these white plaques occasionally exhibited detaching of small fragments (i.e., desquamation). Similar plaques were found in the lower anterior vestibular attached gingiva. ACS to toothpaste was the main diagnostic hypothesis, but pseudomembranous candidiasis and hyperplastic candidiasis were also considered. The replacement of the toothpaste was immediately provided. Three days after the first consultation, the patient reported a substantial decrease in the oral symptoms and partial remission of white plaques was observed (Figure 2B and 2E). After

four additional days, the patient was asymptomatic and showed complete remission of the oral mucosal lesions (Figure 2C and 2F), supporting the diagnosis of ACS to toothpaste. Throughout the patient's care, the private dentist received remote guidance from the Oral Medicine Service of the Department of Dentistry at PUC Minas.

Case 3

On April 10, 2025, 54-year-old female patient presented to the Oral Medicine Service of Piracicaba

Dental School (OROCENTRO FOP-UNICAMP) for follow-up of prosthetic stomatitis. Upon routine oral clinical examination, an ulcer was identified on the lower right labial mucosa (Figure 3C and 3E). The lesion was approximately 1.5 cm in size, with poor-defined borders and a superficial, irregular ulcerated surface. It was painful upon palpation, and the patient described a burning sensation in the affected area. The ulcer had been evolving for at least one week, with a noticeable increase in size and discomfort over the last few days. Extraoral

Table 1: Clinical-pathological and demographic data of the six reported cases.

Case number	Sex	Age	City/State	Toothpaste brand	Oral symptoms	Types of oral mucosal lesions	Localization of oral lesions	Time to resolution following toothpaste discontinuation	Supplementary treatment
1	Female	66	Belo Horizonte (MG)	Colgate Total Prevenção Ativa®	Burning, discomfort, dryness, roughness	Desquamative gingivitis (erythema and erosion), erythematous macules, ulcers, erosions	Gingiva, oral vestibule, labial mucosa adjacent to buccal mucosa (bilaterally)	4 days	Oral prednisone (20 mg/day for 5 days)
2	Female	11	Patos de Minas (MG)	Colgate Total Prevenção Ativa Antitártaro®	Pain, burning, dysphagia, dyslalia	White plaques, desquamation, erythema	Ventral surface and lateral borders of the tongue (bilaterally), gingiva	7 days	None
3	Female	54	Piracicaba (SP)	Colgate Total Clean Mint®	Pain, burning, discomfort	Ulcers	Lower labial mucosa and lower lip semimucosa	14 days	None
4	Female	33	Piracicaba (SP)	Colgate Total 12 Clean Mint®	Pain	Swelling, ulcers, tongue depapillation, necrosis	Upper labial mucosa, tongue, gingiva	29 days	Intramuscular promethazine hydrochloride, fexofenadine (15 days)
5	Female	33	Belo Horizonte (MG)	Colgate Total Prevenção Ativa Carvão Ativado®	Pain, dysphagia, dyslalia	Ulcers	Gingiva, lateral borders and ventral surface of the tongue, buccal mucosa, floor of the mouth	7 days	Photobiomodulation therapy (PBMT), benzydamine hydrochloride mouthwash
6	Male	36	Campos Gerais (MG)	Colgate Total Prevenção Ativa Clean Mint®	Pain, dysphagia	Ulcers, erythematous macules, vesicles	Tongue, labial and buccal mucosa, floor of the mouth and soft palate	7 days	Intramuscular Diprospan® (5 mg of betamethasone dipropionate and 2 mg of betamethasone disodium phosphate)

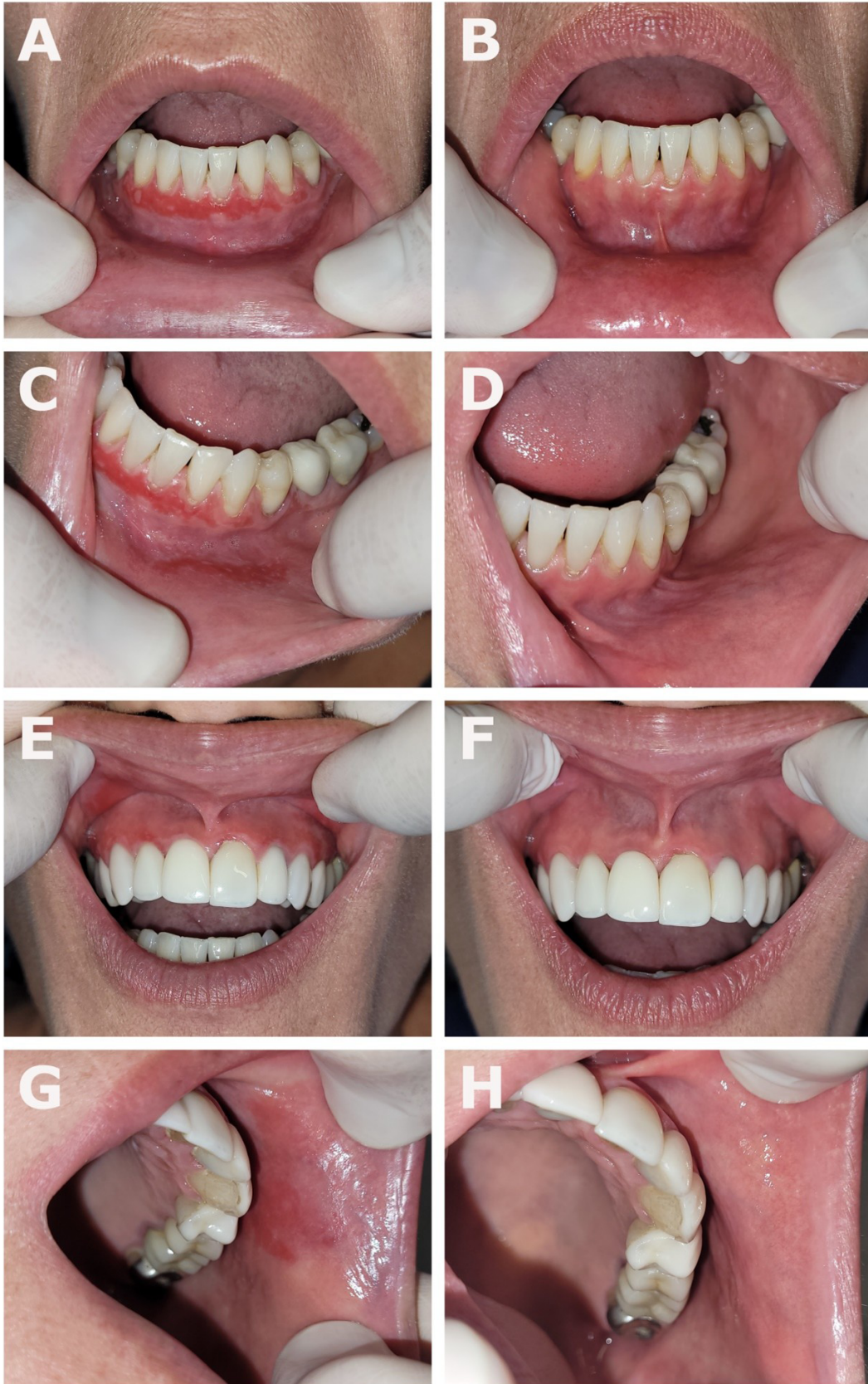


Figure 1. Clinical presentation of case 1. (A, C, E, G) Initial consultation. (B, D, F, H) Follow-up 10 days after the initial consultation.

examination revealed a corresponding erythematous ulcer on the lower lip semimucosa, with dry, yellowish crusts in its edges (Figure 3A). The patient reported mild burning in the oral mucosa, which was consistent with the intraoral findings. The patient had a medical history of systemic hypertension, for which she is treated with atenolol and benazepril, and migraines, for which she is treated with topiramate. Upon further inquiry into recent changes in oral care products, the patient revealed that she had started using Colgate Total Clean Mint® toothpaste 14 days prior. Since the initiation of this product,

the burning sensation progressively exacerbated, and the mucosal ulcers appeared approximately one week later. The symptoms were aggravated with continued use, leading to a noticeable worsening of the lesions. The patient was advised to discontinue the use of the toothpaste immediately, and a follow-up appointment was scheduled. At the follow-up appointment, 14 days after discontinuing the toothpaste, the intraoral ulcer had completely healed, with no visible remnants of the lesion (Figure 3D and 3F). The mucosa appeared smooth and intact, and the patient reported no pain or burning

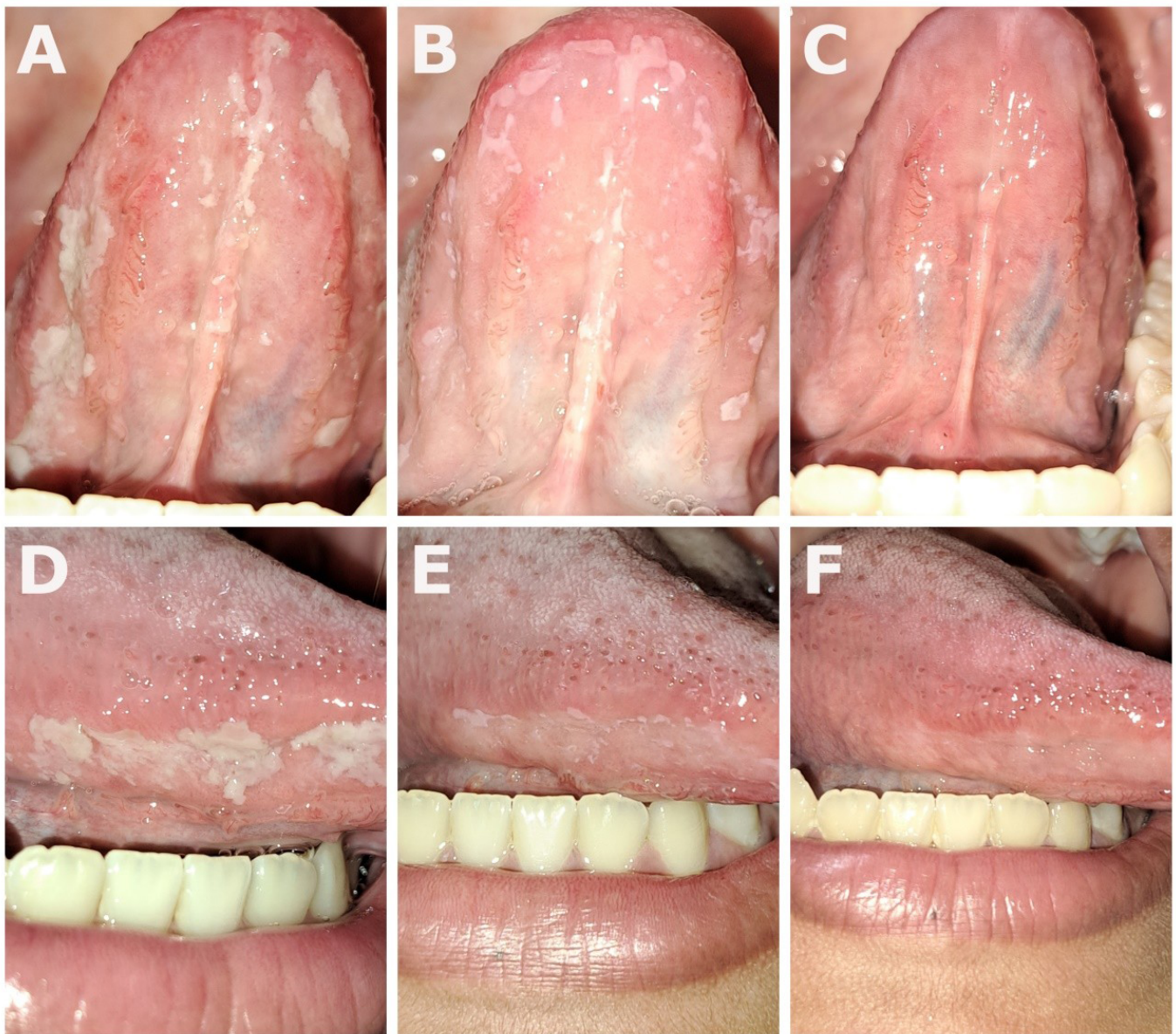

Figure 2. Clinical presentation of case 2. (A, D) Initial consultation. (B, E) Follow-up 3 days after discontinuing the toothpaste. (C, F) Follow-up 7 days after discontinuing the toothpaste.

sensations. The extraoral lesion had also significantly improved. The erythema persisted but was markedly reduced in intensity. The crusts on the semimucosal lesion had fallen off, leaving a smooth, discreet erythematous area (Figure 3B). The patient reported complete relief from the burning sensation and discomfort, with no signs of recurrence, supporting the diagnosis of ACS to

toothpaste. The patient was advised to maintain regular follow-up for continued monitoring.

Case 4

On May 29th, 2025, a 33-year-old female presented to the OROCENTRO FOP-UNICAMP reporting that, approximately three weeks earlier, she had begun

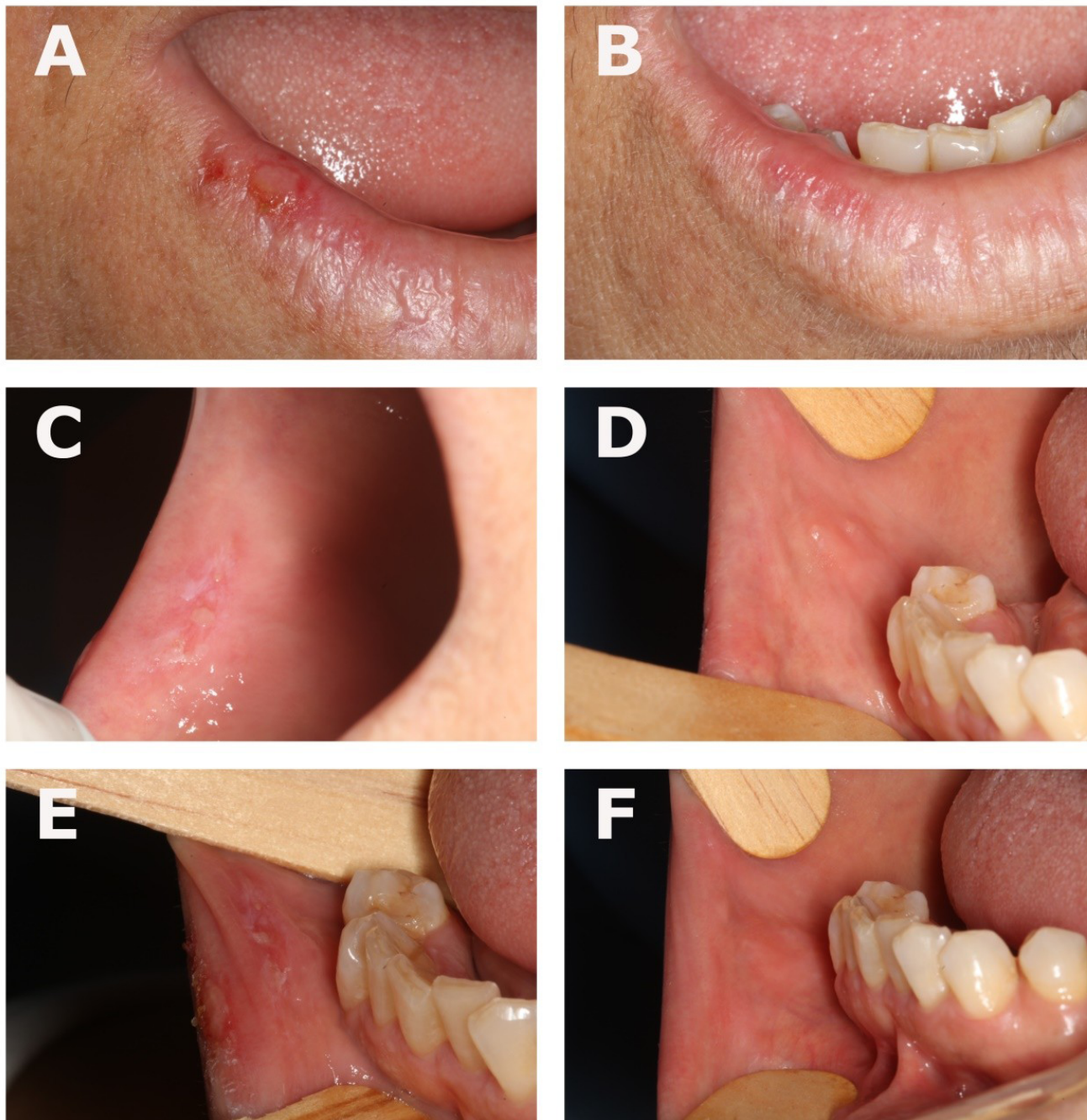


Figure 3. Clinical presentation of case 3. (A, C, E) Initial consultation. (B, D, F) Follow-up 14 days after discontinuing the toothpaste.

experiencing soreness in the oral mucosa. Following the ingestion of orange juice, she developed swelling of the upper lip, gingiva, and tongue, accompanied by pain. On the same day, she sought emergency care, where she received intramuscular promethazine hydrochloride injection. The edema began to subside shortly after administration; however, the patient subsequently developed painful ulcerations throughout the oral mucosa. During the anamnesis, the only systemic medication reported was an oral contraceptive. Further inquiry regarding oral hygiene habits revealed prior use of Colgate Total 12 Clean Mint® toothpaste. The patient confirmed regular use of the product and presented a photograph of the packaging for verification. Intraoral examination revealed ulcerations on the upper labial mucosa, depapillation of the tongue (Figure 4A and 4C), and whitish, desquamative interdental papillae suggestive of localized necrosis in the regions of teeth 14 to 16 (Figure 4E) and 24 to 26 (Figure 4G). The patient had discontinued the use of the toothpaste two weeks prior to the consultation and had switched to another brand. She also reported a consultation with an allergist, who prescribed fexofenadine for 15 days. Although she experienced partial improvement, she continued to report persistent discomfort, which interfered with normal eating. The OROCENTRO team then recommended that she maintain the prescribed antihistamine regimen, avoid spicy condiments and acidic foods, and transition to a neutral toothpaste. At the 15-day follow-up, the patient returned in good general condition, reporting resolution of pain and overall clinical improvement. She had been using a neutral toothpaste as advised and found it beneficial. However, she reported a recent episode of symptom exacerbation, which she attributed to consuming movie theater popcorn. Extraoral examination revealed no significant findings, and no labial edema was noted. Intraorally, the mucosa appeared normochromic and well-hydrated, with no ulceration or areas of necrosis (Figure 4B, 4D, 4F and 4H), supporting the diagnosis of ACS to toothpaste. A mild erythema was observed in the attached gingiva in the region of teeth 24 to 26 (Figure 4H). The patient remains under follow-up with the OROCENTRO team. She was advised to continue using neutral toothpaste and to avoid dietary triggers known to exacerbate symptoms.

Case 5

On March 27, 2025, a 33-year-old female patient was admitted to the Oral Medicine Service of the School of Dentistry at Universidade Federal de Minas Gerais (UFMG) with complaints of intense pain affecting multiple areas of the oral cavity, which

had started approximately a month before. The patient reported a previous dental consultation, during which the professional prescribed fluconazole, prednisone, and chlorhexidine mouthwash. Due to lack of improvement, triamcinolone acetonide topical ointment was later prescribed, which, according to the patient, worsened her clinical condition. At the time of this first consultation, she was self-medicating with ibuprofen and using an oral topical formulation containing neomycin sulfate, sodium bismuth tartrate, and procaine hydrochloride for symptomatic relief. The patient also reported poor nutritional intake, an approximate weight loss of 6 kg, and difficulty speaking and swallowing. She denied any known systemic conditions, regular use of medications, smoking, or alcohol consumption. Intraoral examination revealed multiple ulcers of varying sizes, ranging from punctate lesions to larger areas, diffusely distributed across the oral mucosa. Lesions were observed in both keratinized and non-keratinized mucosal sites, including gingiva (Figure 5A and 5B), lateral borders of the tongue (Figure 5C and 5D), buccal mucosa, floor of the mouth, and ventral surface of the tongue. Due to the unusual clinical presentation and considering the epidemiological context at that time in Brazil, further anamnesis included a detailed inquiry about the toothpaste in use. The patient reported recent use Colgate Total Prevenção Ativa Carvão Ativado® toothpaste. Based on this information, the clinical management included photobiomodulation therapy (PBMT) (Therapy EC, DMC, São Carlos, Brazil, wavelength 660 nm and power of 100 mW), applied at 3J for 30 seconds per point. The application sites included three points on the buccal gingiva of both upper and lower arches, one point at the tongue apex, two points on each lateral border of the tongue, and two points on the floor of the mouth. The patient was advised to discontinue the use of the current toothpaste and replace it with a pediatric formulation. Additionally, benzydamine hydrochloride mouthwash was prescribed for use before meals. At the 7-day follow-up visit, the patient reported having followed the recommendations and noted significant symptomatic improvement. Intraoral examination revealed complete resolution of the ulcerative lesions (Figure 5E and 5F), with no new lesions observed, supporting the diagnosis of ACS to toothpaste. The patient was discharged with guidance regarding future product use.

Case 6

On March 23, 2025, a 36-year-old male patient was referred to the Oral Medicine Service of the School

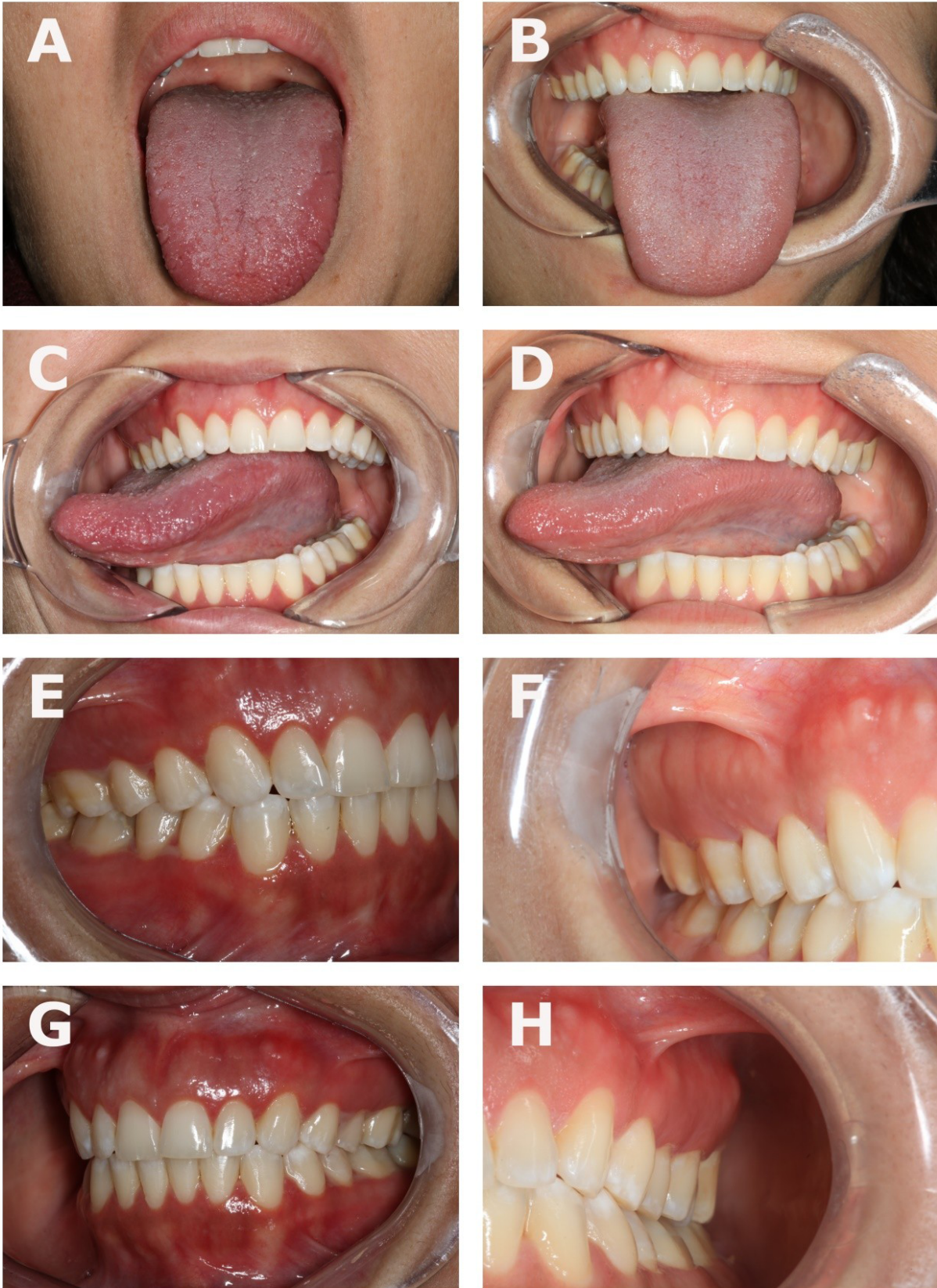


Figure 4. Clinical presentation of case 4. (A, C, E, G) Initial consultation. (B, D, F, H) Follow-up 15 days after discontinuing the toothpaste.

of Dentistry at Universidade Federal de Alfenas (UNI-FAL), by an infectious disease specialist, for evaluation of lesions in the oral mucosa. During the anamnesis, the patient reported the appearance of painful ulcerated lesions involving the tongue, labial and buccal mucosa, floor of the mouth, and soft palate for approximately 15 days. The patient did not report significant systemic

changes and stated that she was taking valsartan and gabapentin. The physician had prescribed nystatin oral suspension and requested serological tests for anti-HIV, anti-Hepatitis, and VDRL, all of which were negative. As there was no improvement in the lesions, the patient was referred to oral medicine evaluation. The intra-oral physical examination revealed the presence of

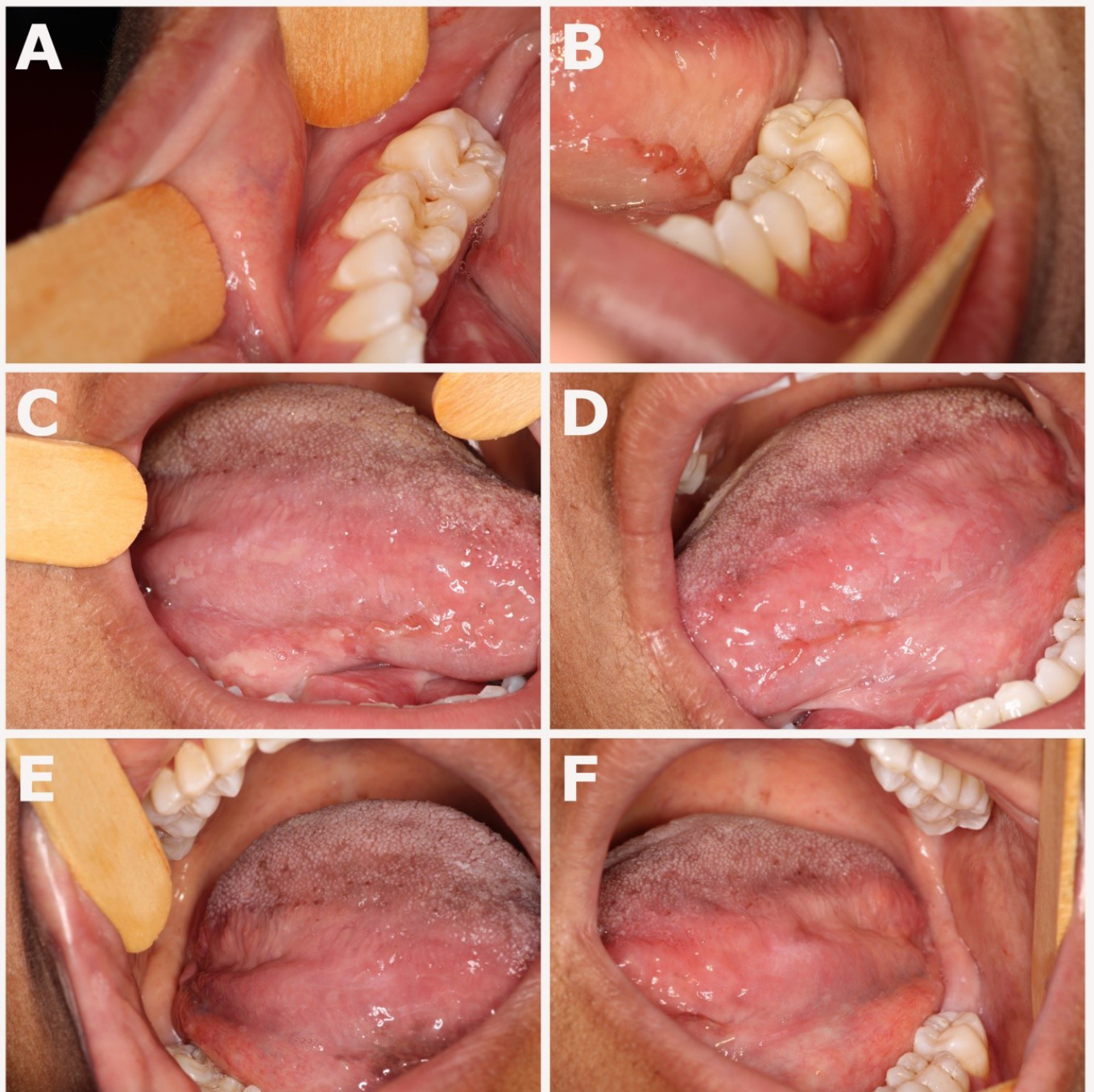


Figure 5. Clinical presentation of case 5. (A, B, C, D) Initial consultation. (E, G) Follow-up 7 days after discontinuing the toothpaste.

erythematous macules, with vesicles in the center, located in the posterior region of the soft palate and causing dysphagia (Figure 6A and 6B). The other regions of the oral mucosa were normal at the time of this first oral medicine consultation. Although the clinical presentation could suggest a traumatic lesion, there was no history of trauma in the area, and the prior occurrence of multiple lesions in different sites makes this hypothesis unlikely. The patient was asked which toothpaste he was using and if he had changed it recently. He reported that he had recently started using Colgate Total Prevenção Ativa Clean Mint® toothpaste. Therefore, the patient was advised to stop using this toothpaste and a single dose of intramuscular Diprosan® was prescribed. Diprosan (1 mL/ampule) is composed of 5 mg of betamethasone dipropionate and 2 mg of betamethasone disodium phosphate in a sterile buffered vehicle. After seven days,

the lesions had completely regressed and a complete remission of the symptoms was observed, supporting the diagnosis of ACS to toothpaste.

DISCUSSION

Although contact hypersensitivity reactions are very common in the skin, where they are referred to as allergic contact dermatitis, contact allergy in the oral mucosa is less prevalent in clinical practice. These oral mucosal hypersensitivity reactions are therefore a more complex diagnostic and therapeutic challenge, given their varied clinical presentation, nonspecific histopathological features, and less robust evidence for the use of patch testing⁴.

ACS involves a T-lymphocyte-mediated immune response (delayed-type or type IV). Nevertheless, the mechanisms by which allergens activate T lymphocytes are not completely known³. The type IV reactions occur in genetically susceptible individuals after second or subsequent contact exposure to an exogenous allergen. Many allergens are haptens, small molecules which need to associate with a host protein to become immunogenic. In a first contact, the hapten-protein complex is captured by antigen-presenting cells, such as dendritic cells, and taken to regional lymph nodes to be presented to naïve T lymphocytes, through molecules of the major histocompatibility complex (MHC). After activation and clonal expansion, memory CD4+ T and CD8+ T lymphocytes are generated, which can be activated in subsequent exposures to the allergen. Depending on the nature of the sensitizing agent and the cytokine microenvironment, T lymphocytes can differentiate into distinct subpopulations, characterized by the production of different cytokine profiles and consequently by the activation of different effector mechanisms. In contact hypersensitivity reactions, activation of Th1 memory lymphocytes leads to the production of the cytokines interferon-gamma (IFN- γ) and tumor necrosis factor-alpha (TNF- α) with the consequent recruitment and activation of macrophages, cytotoxic T (Tc) lymphocytes and natural killer cells. The production of inflammatory mediators, such as reactive oxygen species, enzymes and other molecules by immune cells causes the changes and tissue damage that characterize the clinical manifestations²².

A relevant study, published by de Groot²³, critically reviewed the literature regarding contact allergy to toothpastes ingredients, between 1900 and 2016. According to the author, the main manifestation of hypersensitivity reaction to toothpaste is cheilitis, with or without perioral dermatitis, commonly characterized by dry lips, mild

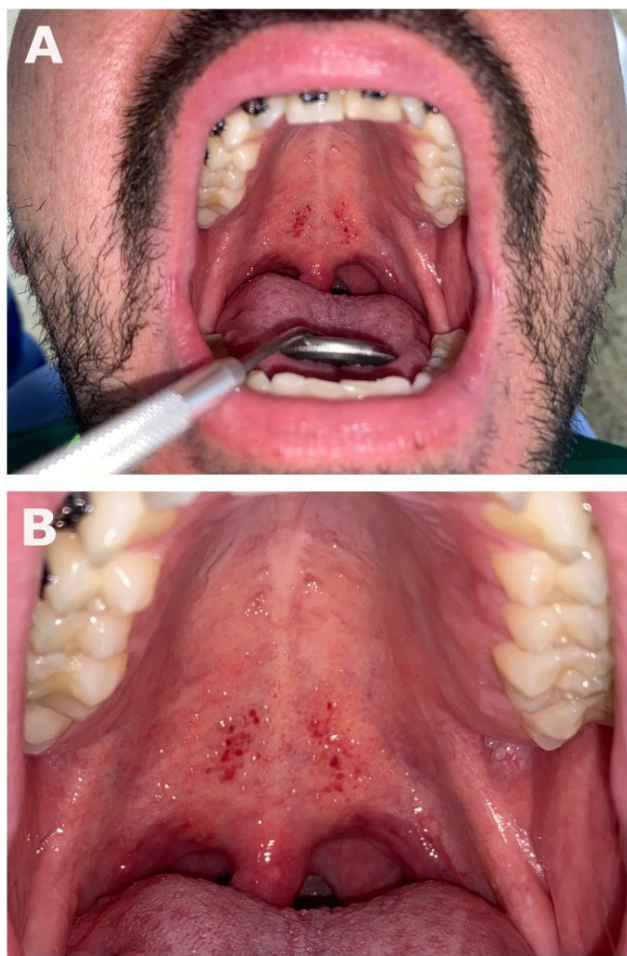


Figure 6. Clinical presentation of case 6. (A, B) Initial consultation at the oral medicine service.

erythema, swelling, fissures and angular cheilitis. Oral mucosa involvement is less prevalent and usually described as stomatitis, glossitis/tongue swelling, and/or gingivitis. Oral signs include swelling, erythema, vesicles, ulcers and desquamation. The oral symptoms, usually more prominent than the signs, include numbness, burning sensation, soreness and ageusia. Dermatitis on the hand holding the toothbrush is also reported. The time between the start of toothpaste use and the allergic reactions may vary from less than 2 weeks to years. Resolution of clinical manifestations usually occurs after cessation of the toothpaste use. The author emphasizes that toothpastes are complex formulations, usually showing more than 20 different constituents. In this regard, the major functional classes of toothpaste constituents are abrasives, fluoride, humectants, flavoring agents, sweeteners, thickening agents, detergents, coloring materials and water. Diverse chemicals were implicated as possible contact allergens in toothpastes, with different reliability levels and risk of analysis bias, suggesting a non-specific pattern of toothpaste components causing contact allergy. Finally, this review article stated that there is no consensus on the patch testing method to study contact allergy to toothpastes.

Among the main differential diagnoses of ACS are irritant contact stomatitis, erythroplakia, erythroleukoplakia, lichen planus, plasma cell gingivitis, oral manifestations of anemia, pemphigus vulgaris and pemphigoid³.

The management of ACS initially involves a provisional clinical diagnosis based on clinical history and physical examination. Subsequently, withdrawing of the possible allergen is a key action. Afterward, complete resolution of the clinical manifestations supports the diagnosis of ACS. A biopsy may be indicated in cases with no or partial clinical improvement. After that, histopathological characteristics of a disease with no features of allergic reaction should involve specific diagnostic and therapeutic approaches, if necessary. Histopathological characteristics consistent with allergic reaction may demand a patch test. If the patch test is positive for a particular allergen, clinical resolution is expected after removing this substance. In case of a negative patch test, different modalities of corticosteroid treatment should be considered, with expectation of resolution. In case of recurrence after some time, a new patch test may be considered³.

Wang and Woo²⁴ disclosed that ACS may exhibit two different histological patterns: the first one shows sub-epithelial sheets of polyclonal plasma cell infiltrate within the lamina propria (plasma cell stomatitis); in the second pattern, the lamina propria presents a band of lymphohistiocytic infiltrate at the epithelial interface, with or

without well-formed or loosely arranged non-necrotizing granulomas that frequently shows deep peri/paravascular location (often diagnosed as lichenoid and granulomatous inflammation, highlighting a clinical correlation).

As previously stated, the management of ACS is primarily based on discontinuing exposure to the potential allergen³. Additionally, as observed in the reported cases, topical and systemic agents such as corticosteroids and antihistamines may be prescribed for symptomatic relief. In case #5 specifically, the clinical presentation consisted of multifocal and confluent ulcerated oral lesions of approximately one month's duration, accompanied by severe pain, functional impairment, and significant weight loss. Given this scenario, PBMT was employed due to its ability to promote immunomodulation, reduce the inflammatory process, control pain, and accelerate healing^{25,26}. It is interesting to highlight that a recent study using an experimental model of allergic contact dermatitis indicates that PBMT significantly inhibits its development, mainly due to its ability to suppress T-cell activation²⁷, which plays a central role in the pathogenesis of type IV reactions²².

It is important to emphasize that, as toothpastes serve as vehicles for therapeutic agents that promote individual and community oral health, Cury and Tenu-ta²⁸ highlight the importance of basing their use on the best scientific evidence. In this regard, these authors underline that, among other evidence: the most important therapeutic agent of toothpaste is fluoride; strong scientific evidence supports that fluoride toothpaste decreases the risk of dental caries; there is scientific evidence that stannous fluoride toothpaste is effective in decreasing dental biofilm and gingivitis.

Among the limitations of the present study, it is important to underscore that no histological analysis nor patch testing were performed in the cases reported in this series. Nonetheless, as previously mentioned, it should be noted that ACS is usually diagnosed based on anamnesis and physical examination, and a biopsy may be indicated in cases with absent or partial clinical improvement after removal of the possible allergen³. Moreover, despite the low consensus regarding the patch test method to investigate ACS to toothpaste²³, future studies should consider the cautious use of this method, especially in cases where biopsy is indicated and after histopathological analysis consistent with an allergic reaction, as discussed previously³.

Within the limitations of a case series study, this manuscript highlights a potential association between certain toothpaste formulations and ACS. The recent multiple

cases clinically consistent with ACS to toothpaste in Brazil should be carefully evaluated, using the best available scientific evidence. The investigation of a probable allergenic substance should consider that toothpastes are complex formulations with several different constituents. In this regard, it remains premature to point out which component of the new formulation of Colgate-Palmolive toothpaste containing stannous fluoride should be responsible for the events compatible with ACS reported in Brazil. In this context, dentists must be aware of the clinical manifestations of ACS to toothpaste, as well as realize that treatment usually involves discontinuation of the product.

CONCLUSION

This multicenter retrospective case series reported six well-illustrated cases clinically consistent with ACS to the new formulation of Colgate-Palmolive toothpaste containing stannous fluoride. All patients presented acute oral symptoms including burning, pain, dysphagia, and dyslalia. Clinical signs included erythematous macules, white plaques, desquamation, vesicles, erosions and ulcers affecting different oral sites. The oral lesions typically resolved within 4 to 29 days after toothpaste discontinuation, with or without pharmacologic intervention. No cases required biopsy or patch testing. In all cases, the temporal relationship and complete remission following toothpaste withdrawal supported the diagnosis of ACS.

AUTHORS' CONTRIBUTIONS

BAR: Conceptualization, Writing – original draft, Writing – review & editing. GVR: Conceptualization, Writing – original draft, Writing – review & editing. LB: Conceptualization, Writing – original draft, Writing – review & editing. GRS: Conceptualization, Writing – original draft, Writing – review & editing. SMCG: Conceptualization, Writing – original draft, Writing – review & editing. PEAS: Conceptualization, Writing – original draft, Writing – review & editing. RVS: Conceptualization, Writing – original draft, Writing – review & editing. ARSS: Conceptualization, Supervision, Writing – original draft, Writing – review & editing. MAL: Conceptualization, Writing – original draft, Writing – review & editing. TCEP: Conceptualization, Writing – original draft, Writing – review & editing. MCFA: Conceptualization, Supervision, Writing – original draft, Writing – review & editing. HPF: Conceptualization, Writing – original draft, Writing – review & editing. RAS: Conceptualization, Writing – original draft, Writing

– review & editing. JACH: Conceptualization, Supervision, Writing – original draft, Writing – review & editing. MCRH: Conceptualization, Supervision, Writing – original draft, Writing – review & editing.

CONFLICT OF INTEREST STATEMENT

Funding: This study was financed in part by the Coordenação de Aperfeiçoamento de Pessoal de Nível Superior – Brasil (CAPES) – Finance Code 001. The authors are also grateful to the Conselho Nacional de Desenvolvimento Científico e Tecnológico (CNPq) and the Fundação de Amparo à Pesquisa do Estado de Minas Gerais (FAPEMIG).

Competing interests: The authors have no relevant financial or non-financial interests to disclose.

Ethics approval: This multicenter study was approved by the Ethical Research Committees at the Pontifícia Universidade Católica de Minas Gerais (PUC Minas) (CAAE: 88903725.7.3003.5137), at the Piracicaba Dental School, University of Campinas (FOP-UNICAMP) (CAAE: 88903725.7.0000.5418), at the Federal University of Minas Gerais (UFMG) (CAAE: 88903725.7.3002.5149) and at the Federal University of Alfenas (UNIFAL) (CAAE: 88903725.7.3001.5142).

REFERENCES

1. De Rossi SS, Greenberg MS. Intraoral contact allergy: a literature review and case reports. *J Am Dent Assoc.* 1998;129(10):1435–41. <https://doi.org/10.14219/jada.archive.1998.0078>
2. AAOM Clinical Practice Statement: subject: oral contact allergy. *Oral Surg Oral Med Oral Pathol Oral Radiol.* 2016;122(1):50–2. <https://doi.org/10.1016/j.o000.2016.02.016>
3. Feller L, Wood NH, Khammissa RAG, Lemmer J. Review: allergic contact stomatitis. *Oral Surg Oral Med Oral Pathol Oral Radiol.* 2017;123(5):559–65. <https://doi.org/10.1016/j.o000.2017.02.007>
4. Reinhart JP, Stoopler ET, Crawford GH. Oral hypersensitivity reactions. *Dermatol Clin.* 2020;38(4):467–76. <https://doi.org/10.1016/j.det.2020.05.007>
5. Brasil. Ministério da Saúde. Agência Nacional de Vigilância Sanitária. Alerta GGMON nº 03/2025 (cosmetovigilância): reações adversas a cremes dentais com fluoreto estanoso – relate os sintomas! [Internet]. Brasília: Ministério da Saúde (Brasil); 2025 [cited 2025 April 17]. Available from: https://antigo.anvisa.gov.br/informacoes-tecnicas/13?p_p_id=101_INSTANCE_R6VaZWzQDDzS&p_col_id=column-1&p_col_count=1&_101_INSTANCE_R6VaZWzQDDzS_groupId=33868&_101_INSTANCE_R6VaZWzQDDzS_urlTitle=alerta-ggmon-n-xx-2025-cosmetovigilancia-reacoes-adversas-a-cremes-dentais-com-fluoreto-estanoso-relate-os-sintomas-&_101_INSTANCE_R6VaZWzQDDzS_struts_action=%2Fasset_publisher%2Fview_content&_101_INSTANCE_R6VaZWzQDDzS_assetEntryId=7005719&_101_INSTANCE_R6VaZWzQDDzS_type=content

6. Brasil. Ministério da Saúde. Agência Nacional de Vigilância Sanitária. 4ª Diretoria/Gerência-Geral de Inspeção e Fiscalização Sanitária. Resolução-RE nº 1.158, de 26 de março de 2025 [Internet]. Brasília: Ministério da Saúde; 2025 [cited 2025 March 28]. Available from: <https://www.in.gov.br/en/web/dou/-/resolucao-re-n-1.158-de-26-de-marco-de-2025-620104001>
7. Brasil. Ministério da Saúde. Agência Nacional de Vigilância Sanitária. Anvisa interdita creme Colgate Total Clean Mint [Internet]. Brasília: Ministério da Saúde; 2025 [cited 2025 July 1]. Available from: <https://www.gov.br/anvisa/pt-br/assuntos/noticias-anvisa/2025/anvisa-interdita-creme-colgate-total-clean-mint>
8. Globo Comunicação e Participações S.A. Colgate diz que pessoas podem ter sensibilidade a ingredientes de pasta interdita pela Anvisa [Internet]. Rio de Janeiro: Redação g1; 2025 [cited 2025 March 30]. Available from: <https://g1.globo.com/saude/noticia/2025/03/28/colgate-diz-que-pessoas-podem-ter-sensibilidade-a-ingredientes-de-pasta-interditada-pela-anvisa.ghtml>
9. CNN Brasil. Anvisa proíbe venda de creme dental Colgate após efeitos adversos [Internet]. São Paulo: CNN Brasil; 2025 [cited 2026 January 27]. Available from: <https://www.cnnbrasil.com.br/nacional/brasil/anvisa-proibe-venda-de-creme-dental-colgate-apos-efeitos-adversos/>
10. Brasil. Ministério da Saúde. Agência Nacional de Vigilância Sanitária. Produto Colgate Total Clean Mint segue interdito [Internet]. Brasília: Ministério da Saúde; 2025 [cited 2025 May 2]. Available from: <https://www.gov.br/anvisa/pt-br/assuntos/noticias-anvisa/2025/produto-colgate-total-clean-mint-segue-interditado>
11. Globo Comunicação e Participações S.A. Anvisa volta a interditar pasta de dente da Colgate após marca retirar recurso [Internet]. Rio de Janeiro: Redação g1; 2025 [cited 2026 January 26]. Available from: <https://g1.globo.com/saude/noticia/2025/05/01/anvisa-volta-a-interditar-pasta-de-dente-da-colgate.ghtml>
12. CNN Brasil. Anvisa volta a proibir venda de pasta de dente da Colgate [Internet]. São Paulo: CNN Brasil; 2025 [cited 2026 January 27]. Available from: <https://www.cnnbrasil.com.br/nacional/brasil/anvisa-volta-a-proibir-venda-de-pasta-de-dente-da-colgate/>
13. Colgate-Palmolive Brasil. Comunicado aos nossos consumidores. Colgate Total Clean Mint [Internet]. Instagram; 2025 [cited 2025 July 2]. Available from: <https://www.instagram.com/p/DLViPx5v01F/>
14. Colgate-Palmolive Brasil. Comunicado aos nossos consumidores – Colgate Total Clean Mint [Internet]. São Paulo: Colgate-Palmolive Brasil; 2025 [cited 2026 January 27]. Available from: <https://www.colgate.com.br/colgate-clean-mint-discontinuation>
15. O GLOBO. Após reações alérgicas, Colgate decide parar de fabricar creme dental Clean Mint [Internet]. São Paulo: O GLOBO; 2025 [cited 2025 July 2]. Available from: <https://oglobo.globo.com/saude/noticia/2025/06/26/apos-reacoes-alergicas-colgate-decide-parar-de-fabricar-creme-dental-clean-mint.ghtml>
16. El País México. La alerta sanitaria por el uso del dentífrico Colgate Total Clean Mint se extiende por América Latina [Internet]. Ciudad de México: El País; 2025 [cited 2026 January 27]. Available from: <https://elpais.com/mexico/2025-08-09/la-alerta-sanitaria-por-el-uso-del-dentifrico-colgate-total-clean-mint-se-extiende-por-america-latina.html>
17. Presidencia de la Nación República Argentina. Legislación y Avisos Oficiales. Administración Nacional de Medicamentos, Alimentos y Tecnología Médica. Disposición 5126/2025 [Internet]. Buenos Aires: Boletín Oficial de la República Argentina; 2025 [cited 2026 January 27]. Available from: <https://www.boletinoficial.gob.ar/detalleAviso/primera/328707/20250722>
18. Instituto Nacional de Vigilancia de Medicamentos y Alimentos. El Invima adelanta medidas de vigilancia sanitaria sobre pastas dentales [Internet]. Bogotá: INVIMA; 2025 [cited 2026 January 27]. Available from: <https://invima.gov.co/blog/salade-prensa-13/el-invima-adelanta-medidas-de-vigilancia-sanitaria-sobre-pastas-dentales-168>
19. Instituto de Salud Pública de Chile. Nota informativa asociada a alerta de retiro del mercado N° 23/25 del producto cosmético Colgate Total Clean Mint Crema Dental Anticaries con Flúor [Internet]. Santiago de Chile: ISP; 2025 [cited 2026 January 27]. Available from: <https://www.ispch.cl/wp-content/uploads/2025/06/nota-colgate.pdf>
20. Comisión Federal para la Protección contra Riesgos Sanitarios. Aviso de riesgo. Colgate Total prevención activa Clean Mint [Internet]. Instagram; 2025. [cited 2026 January 29]. Available from: <https://www.instagram.com/p/DNCLv-7RNP2/?igsh=MxJubGczeDduejJ1MQ%3D%3D>
21. Comisión Federal para la Protección contra Riesgos Sanitarios. Aviso de Riesgo: Sobre el retiro del mercado del producto Colgate Total® Prevención Activa CLEAN MINT [Internet]. Ciudad de México: Secretaría de Salud; 2025 [cited 2026 January 29]. Available from: <https://lopezdoriga.com/wp-content/uploads/2025/08/aviso-de-riesgo-colgate-04082025.pdf>
22. Jutel M, Agache I, Zemelka-Wiacek M, Akdis M, Chivato T, Del Giacco S, et al. Nomenclature of allergic diseases and hypersensitivity reactions: adapted to modern needs: an EAACI position paper. *Allergy*. 2023;78(11):2851-74. <https://doi.org/10.1111/all.15889>
23. de Groot A. Contact allergy to (ingredients of) toothpastes. *Dermatitis*. 2017;28(2):95-114. <https://doi.org/10.1097/DER.0000000000000255>
24. Wang D, Woo SB. Histopathologic spectrum of intraoral irritant and contact hypersensitivity reactions: a series of 12 cases. *Head Neck Pathol*. 2021;15(4):1172-84. <https://doi.org/10.1007/s12105-021-01330-8>
25. Chung H, Dai T, Sharma SK, Huang YY, Carroll JD, Hamblin MR. The nuts and bolts of low-level laser (light) therapy. *Ann Biomed Eng*. 2012;40(2):516-33. <https://doi.org/10.1007/s10439-011-0454-7>
26. Al Balah OF, Rafie M, Osama AR. Immunomodulatory effects of photobiomodulation: a comprehensive review. *Lasers Med Sci*. 2025;40(1):187. <https://doi.org/10.1007/s10103-025-04417-8>
27. Fu J, Zhao R, Jiang Y, Chen Y, Du J, Liu Y, et al. Photobiomodulation suppresses allergic contact dermatitis by inhibiting T-cell activation. *Contact Dermatitis*. 2025;92(3):187-96. <https://doi.org/10.1111/cod.14713>
28. Cury JA, Tenuta LMA. Evidence-based recommendation on toothpaste use. *Braz Oral Res*. 2014;28(Spec No):1-7. <https://doi.org/10.1590/S1806-83242014.50000001>