


Clinical presentation heterogeneity of HSV₁ oral lesions in immunosuppressed patients

Roberta Targa Stramandinoli-Zanicotti ¹
Carolina Eurich Mazur ¹
Juliana Lucena Schussel ¹
José Miguel Amenábar ¹
Cassius C Torres-Pereira ^{1*} 

Abstract:

Herpes simplex virus type 1 (HSV-1) may be considered the main etiological viral agent in oral infections. As its symptoms bear similarity with other oral lesions within immunosuppressed patients, the diagnosis of herpes may be mistaken for other diseases. Therefore, the investigation of a technique that better detects this virus is important to assure a treatment that is more effective and adequate for this case. The study aimed to describe four cases of immunosuppressed patients presenting HSV-1 lesions, whose diagnosis was confirmed using polymerase chain reaction (PCR). Four hematopoietic stem cell transplant patients referred to the dental clinic complaining about oral lesions, pain, and functional difficulties. Multiple ulcers were observed in different sites of the mouth. Exfoliative cytology was performed and the diagnosis was confirmed by qualitative real-time PCR, in which HSV-1 was detected in the four cases. Specific techniques for the diagnosis of viral infections should be instituted for immunosuppressed patients presenting oral ulcers, since opportunistic infections can spread rapidly in these individuals, leading to increased morbidity and mortality.

Keywords: Herpesvirus 1, Human; Stem Cell Transplantation; Oral Manifestation; Polymerase Chain Reaction

¹ Universidade Federal do Paraná,
Departamento de Estomatologia - Curitiba -
Paraná - Brasil

Correspondence to:
Cassius C Torres-Pereira.
E-mail: cassius@ufpr.br

Article received on February 9, 2020.
Article accepted on July 24, 2020.

DOI: 10.5935/2525-5711.20200009



INTRODUCTION

Herpesviridae family is composed of eight virus types that are differentiated either by their structure or by their features in human infections. The most common type spread among the population worldwide is the Herpes Simplex Virus (HSV), which is classified as an α -herpes virus. It consists of a double-stranded DNA, with structural proteins forming the virion and genes of reactivation and establishment. This is a neurotropic virus, since it causes latent infection in neural ganglia and, migrates to the oral or genital epithelium^{1,2} during immunosuppression period.

Herpes Simplex virus type 1 (HSV-1) is the most common *Herpesviridae* family virus that presents oral manifestations^{2,3}. HSV-1 typically initiates a productive lytic infection in the mucosal epithelia and then establishes latency in the trigeminal ganglia after infecting sensory neurons adjacent to the site of the mucosal virus replication. Occasional reactivation can result in recurrent lytic infection in the oral skin and mucosa with virus shedding into the saliva and in some instances, oral lesions⁴. HSV-1 infections are ubiquitous in humans. More than 50% of adults in the US are HSV-1 seropositive, and close to 100% are infected in some parts of the developing world⁵.

The prevalence of HSV-1 oral infections in people with an impaired immune system is significant and requires careful investigation, prophylaxis and specific treatment^{3,6}. One cause for immunosuppression, for example, is hematopoietic stem cell transplantation (HSCT). During this procedure, chemotherapeutic conditioning is used for disease regression and the bone marrow is prepared for the donor's cells engraftment to the recipient. Therefore, at this moment, the patient is susceptible to various complications, such as graft-versus-host disease (GVHD), as well as infections, including the HSV-1 virus⁷.

It is important to emphasize that in immunocompromised patients, viral and non-viral infections may present similar oral manifestation as seen in GVHD cases. Hence, laboratory techniques, such as molecular biology, can help obtain the correct diagnosis and treatment⁶. Among them, qualitative real-time PCR is a rapid and sensitive method for the detection and genotyping of infectious diseases such as herpes viruses. The analysis includes virus isolation in cell culture and detection, followed by immunofluorescence microscopy. Due to

the advances in molecular biology, the real-time PCR enables accurate measurement of viral load associated with herpes virus diseases^{8,9}.

Therefore, this study aims to describe four cases of immunosuppressed patients presenting HSV-1 oral lesions, which were confirmed using PCR.

CASES REPORT

Four cases of patients who are HSCT recipients, presenting atypical manifestations of the HSV-1 virus in the mouth were selected. The main lesion's features were ulcers, pain and impaired oral function. All cases were diagnosed clinically and by exfoliative cytology, which confirmed the diagnosis by qualitative real-time PCR. All patients signed the informed consent form.

CASE 1

A 5-year-old boy with Wiskott-Aldrich syndrome underwent two haploidentical HSCTs with the mother's hematopoietic stem cells. He was submitted by an oral examination two months after the second transplantation, due to variable, symptomatic ulcers in the gingiva, bilateral tongue border, lip mucosa, and hard palate. The patient reported fever and inappetence for two days. Medications used were ganciclovir, co-trimoxazole, and immunosuppressants. Differential clinical diagnoses were oral GVHD and viral infection. The oral swab and PCR confirmed HSV1 infection. The patient was treated with intravenous acyclovir for 15 days, showing no morbidity after the infection's remission (Figure 1).

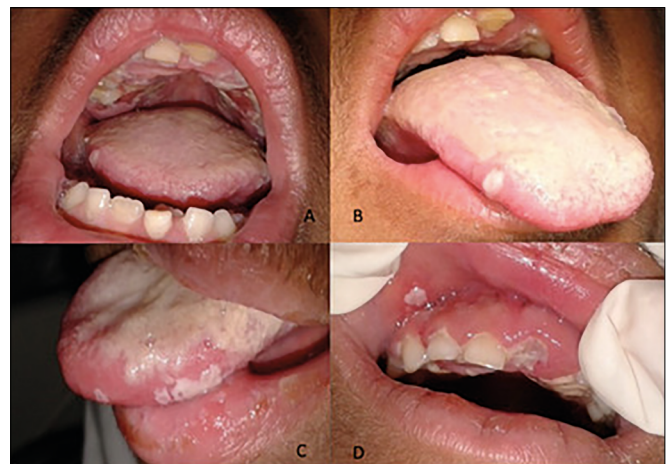

Figure 1. Oral manifestation of HSV1 in a 5-year-old boy with Wiskott-Aldrich syndrome, after transplantation.

CASE 2

An 18-year-old male underwent HSCT-related for acute lymphocytic leukemia (ALL). Two months after HSCT, he was referred for oral examination due to an ulcer of approximately 4 mm in the hard palate, with defined limits and symptomatic. He was taking acyclovir (800 mg/day) and immunosuppressant medication. The patient reported fever and inappetence. Medications used were ganciclovir, Bactrim and immunosuppressant agent. Due to lesion characteristics, the differential clinical diagnosis was a traumatic ulcer. The treatment was symptom relief (Figure 2).

CASE 3

After three years of allogeneic HSCT, a 32-year-old female with severe aplastic anemia, still immunosuppressed due to thrombocytopenia, presented ulcers in the hard palate and right buccal mucosa, symptomatic, evolution period of 4 days. She was taking acyclovir. Differential clinical diagnoses were fungal infection, virus infection and oral GVHD. The patient was treated with intravenous acyclovir, without morbidity after the infection (Figure 3).

CASE 4

After 6 months of unrelated HSCT for ALL, a 41-year-old male with bone marrow aplasia presented ulcerated lesion of the mouth with area vesicles at the lingual apex, bilateral buccal mucosa and posterior right hard palate (figure 4). He was taking antimicrobial and immunosuppressive medication. Differential clinical diagnoses were thrombocytopenia lesions and virus infection. The presence of HSV-1 and local fungal

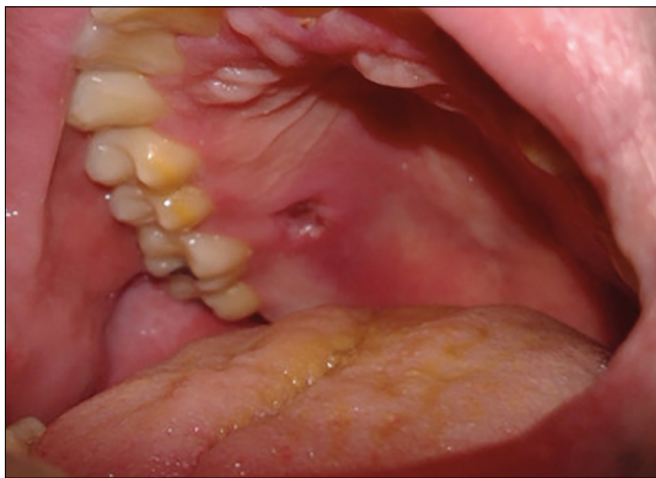

Figure 2. Oral lesions of HSV1 in a 18-year-old male after HSCT for acute lymphocytic leukemia, after transplantation.

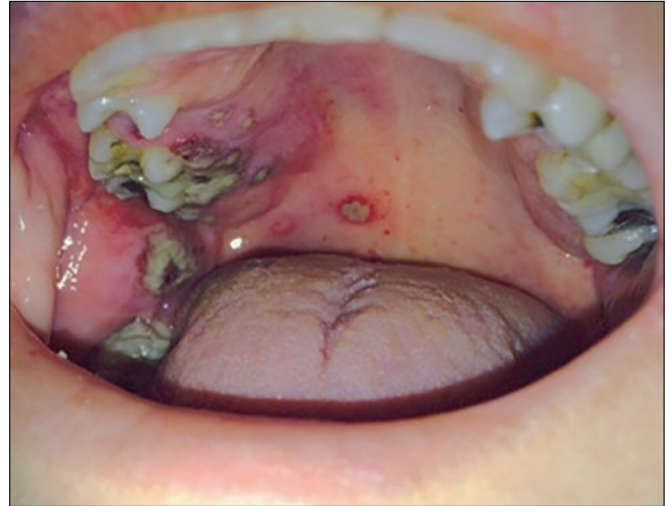


Figure 3. Oral manifestation of HSV1 in a 32-year-old female with severe aplastic anemia, still immunosuppressed due to thrombocytopenia, after transplantation.

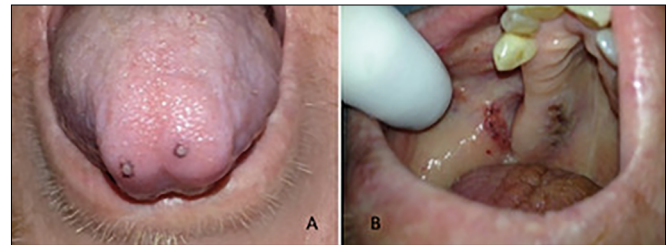


Figure 4: Oral manifestation of HSV1 in a 41-year-old male with bone marrow aplasia, after transplantation.

infection was confirmed by PCR. The patient was treated with intravenous acyclovir, without morbidity after the infection.

DISCUSSION

To diagnose HSV-1 oral lesions in population, in general, is customarily simple, as it does not require additional laboratory techniques to complete the diagnosis. In these cases, supportive treatment and wait for the remission of the lesions that do not carry morbidity and mortality risk is generally sufficient^{8,10}. However, in immunosuppressed individuals, the mouth becomes a favorable site for the appearance of different lesions, which are similar in size, shape, disposition, but caused by different etiological agents¹¹.

In individuals who have undergone HSCT (allogeneic), oral ulcers may arouse not only from HSV-1 infection but also due to graft-versus-host-disease (GVHD). Another possibility of misdiagnosis is erythema, which might as well be white, and result from fungal infection¹². Thus, collecting epithelial tissue

sample for laboratory examination can be an effective alternative in this case, since the treatments for such diseases differ from each other. Incorrect treatment can consequently hamper the healing process. For example, the use of wrong medications in herpetic lesions may increase the risk of the non-healing lesion due to local immunosuppression, while other lesions, such as traumatic ulcers or GVHD lesions are treated with topical immunosuppression. When this treatment is used for viral lesions, there is a delay in the healing process¹³.

To help in the diagnosis at the hospital, the PCR exam can be performed. This method can be applied in all cases of patients suspected of herpes virus infection for the exclusion of other likely diseases. Therefore, laboratory techniques that facilitate the diagnosis of nonspecific oral lesions should be used when it is possible, so the chances of error diagnosis and inadequate treatment can be avoided^{8,14}.

Previously research performed a cross-sectional study to describe oral characteristics and to compare the activation profile of HSV-1 and EBV virus in the saliva of 100 children⁹. Twenty-five were kidney transplanted, 25 with chronic kidney disease and 50 were healthy children. They found that oral involvement by HSV-1 was significantly higher (28%) in transplanted patients than in the other groups. In these cases, two patients were using antiviral, but presented lesions that were positive for HSV-1. Kakiuchi *et al.*¹⁵ demonstrated HSV-1's resistance to acyclovir in patients undergoing HSCT. According to these authors, among the factors that might interfere influence, refractory malignancies are the most likely. In the previous cases, one patient underwent HSCT for refractory leukemia.

In all these cases, early diagnosis and treatment with hospital support were decisive.

CONCLUSION

Suspected HSV-1 infections are justified in ulcerative and persistent lesions of oral tissues in immunocompromised patients. Laboratory confirmation by molecular biology techniques as PCR ensures the diagnosis of the agent and the specific pharmacological dosage for the remission of the lesions, leading to decreased chances of morbidity and mortality and consequent improvement in the patient's quality of life.

REFERENCES

1. Subramaniam A, Britt WJ. Herpesviridae infection: prevention, screening and management. *Clin Obstet Gynecol.* 2018 Mar;61(1):157-76.

2. Andrei G, Georgala A, Topalis D, Fiten P, Aoun M, Opdenakker G, et al. Heterogeneity and evolution of thymidine kinase and DNA polymerase mutants of herpes simplex virus type 1: implications for antiviral therapy. *J Infect Dis.* 2013 Apr;207(8):1295-305.
3. Caliento R, Sarmiento DJS, Silva ÉMP, Tozetto-Mendoza TR, Tobouti PL, Benini V, et al. Oral shedding of HSV-1 and EBV and oral manifestations in paediatric chronic kidney disease patients and renal transplant recipients. *Acta Odontol Scand.* 2018 Feb;76(8):539-44.
4. Aravantinou M, Mizenina O, Calenda G, Kenney J, Frank I, Lifson JD, et al. Experimental oral herpes simplex virus-1 (HSV-1) co-infection in simian immunodeficiency virus (SIV)-infected rhesus macaques. *Front Microbiol.* 2017;8:2342.
5. Looker KJ, Magaret AS, May MT, Turner KME, Vickerman P, Gottlieb SL, et al. Global and regional estimates of prevalent and incident herpes simplex virus type 1 infections in 2012. *PLoS One.* 2015 Oct;10(10):e0140765.
6. Tang FF, Zhao XS, Xu LP, Zhang XH, Chen YH, Mo XD, et al. Risk factors for herpes simplex virus-1/2 viremia and clinical outcomes following unmanipulated haploidentical haematopoietic stem cell transplantation. *J Clin Virol.* 2017 Oct;95:20-5.
7. Roddie C, Peggs KS. Immunotherapy for transplantation-associated viral infections. *J Clin Invest.* 2017 Jun;127(7):2513-22.
8. Sugita S, Shimizu N, Watanabe K, Mizukami M, Morio T, Sugamoto Y, et al. Use of multiplex PCR and real-time PCR to detect human herpes virus genome in ocular fluids of patients with uveitis. *Br J Ophthalmol.* 2008 Jul;92(7):928-32.
9. Fujii H, Kakiuchi S, Tsuji M, Nishimura H, Yoshikawa T, Yamada S, et al. Application of next-generation sequencing to detect acyclovir-resistant herpes simplex virus type 1 variants at low frequency in thymidine kinase gene of the isolates recovered from patients with hematopoietic stem cell transplantation. *J Virol Methods.* 2018 Jan;251:123-8.
10. Lee C, Chi CC, Hsieh SC, Chang CJ, Delamere FM, Peters MC, et al. Interventions for treatment of herpes simplex labialis (cold sores on the lips). *Cochrane Database Syst Rev.* 2011 Oct;2011(10):CD009375.
11. Sepúlveda E, Brethauer U, Rojas J, Fernández E, Le Fort P. Oral ulcers in children under chemotherapy: clinical characteristics and their relation with herpes simplex virus type 1 and Candida albicans. *Med Oral Patol Oral Cir Bucal.* 2005 Apr;(10 Suppl 1):E1-8.
12. Akahoshi Y, Kanda J, Ohno A, Komiya Y, Gomyo A, Hayakawa J, et al. Acyclovir-resistant herpes simplex virus 1 infection early after allogeneic hematopoietic stem cell transplantation with T-cell depletion. *J Infect Chemother.* 2017 Jul;23(7):485-7.
13. Rowe AM, St. Leger AJ, Jeon S, Dhaliwal DK, Knickerbein JE, Hendricks RL. Herpes keratitis. *Prog Retin Eye Res.* 2013 Jan;32:88-101.
14. Sakai K, Wakasugi S, Muchemwa FC, Ihn H. Quick detection of herpes viruses from skin vesicles and exudates without nucleic acid extraction using multiplex PCR. *Biosci Trends.* 2008;2(4):164-8.
15. Kakiuchi S, Tsuji M, Nishimura H, Yoshikawa T, Wang L, Takayama-Ito M, et al. Association of the emergence of acyclovir-resistant herpes simplex virus type 1 with prognosis in hematopoietic stem cell transplantation patients. *J Infect Dis.* 2017 Mar;215(6):865-73.